

HEPATIC HYDROTHORAX: AN UNCOMMON CAUSE OF PLEURAL EFFUSION

Ian Caldeira Ruppen

Ingá University Center – Uningá

<https://orcid.org/0000-0003-1706-1662>

Leandro Hideki Otani

Maringá Image Institute

<https://orcid.org/0009-0000-6832-4907>

Jamile Diogo de Araujo

University Hospital of Maringá

<https://orcid.org/0000-0002-6302-0864>

Guilherme Enzo Giovanelli Mansano

Ingá University Center – Uningá

Mariane Zancanaro Gallina

Ingá University Center – Uningá

<https://orcid.org/0000-0002-5304-7449>

Patrícia de Vilhena Pimenta Neves

Ingá University Center – Uningá

Marcela Castrequini Guimarães do Vale

Ingá University Center – Uningá

Rafaela Castrequini Guimarães do Vale

Ingá University Center – Uningá

Leonardo Rodrigues Narvaes

Ingá University Center – Uningá

Juliano Rodrigues Narvaes

Ingá University Center – Uningá

Vitor Augusto Olivari do Carmo

Ingá University Center – Uningá

All content in this magazine is licensed under a Creative Commons Attribution License. Attribution-Non-Commercial-Non-Derivatives 4.0 International (CC BY-NC-ND 4.0).



Abstract: Hepatic hydrothorax is the accumulation of transudate in the pleural space of patients with decompensated cirrhosis, in the absence of cardiac, pulmonary, or pleural disease. This condition affects approximately 5 to 15% of patients with cirrhosis and is associated with complications such as ascites, hepatic encephalopathy, and increased mortality. The objective of this study is to present a case report of a patient with hepatic hydrothorax due to alcoholic cirrhosis, carried out through electronic medical records and a literature review.

Keywords: Hydrothorax, alcoholic cirrhosis, congestion, vena cava, alcoholism.

INTRODUCTION

Hepatic hydrothorax is an uncommon mechanical complication occurring in patients with liver cirrhosis, in phases of portal hypertension. These patients present an anomaly in the volume of extracellular fluid, which in many cases results in accumulation most commonly in the abdominal cavity (ascites) and, in approximately 5-10% of patients, in the pleural cavity (pleural effusion). Hepatic hydrothorax is defined as a pleural effusion, usually greater than 500 mL in patients with portal hypertension and without primary cardiac, pulmonary, or pleural disease.

OBJECTIVES

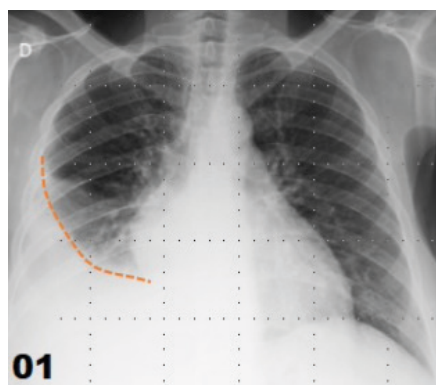
The present study aimed to report a clinical case of a patient with hydrothorax due to alcoholic cirrhotic liver disease, originating from vena cava congestion.

DESIGN AND METHODS

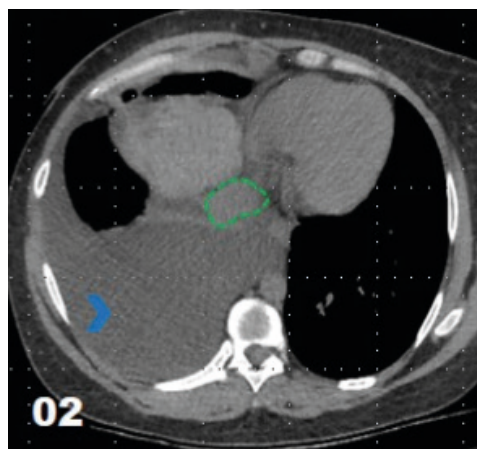
A case report was described retrospectively through research in electronic medical records, in addition to a brief literature review.

CASE REPORT

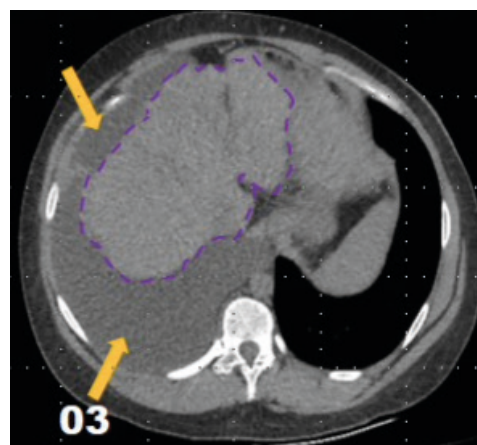
A 36-year-old woman was treated at the hepatology outpatient clinic. She had been an alcoholic for 8 years and had consumed alcohol for 10 years at a dose of approximately 25 g/day. She was diagnosed with alcoholic cirrhosis according to the Child-Pugh B classification. She was referred from the outpatient clinic to the emergency room due to persistent, non-radiating chest pain, especially in the right hemithorax, over the past few months. A chest X-ray (X-ray) was immediately performed to assess the lung parenchyma, which showed significant pleural effusion in the right hemithorax. After the X-ray, a relief thoracentesis was performed, with the collected material sent for analysis of pleural fluid, which demonstrated the criteria for transudate. A chest and abdominal tomography was used to elucidate the cause, which showed signs of chronic liver disease with ascites, splenomegaly, and splenorenal shunt, which determined overload of the inferior vena cava. Given the absence of other findings that could cause significant effusion, hepatic hydrothorax was taken as the main diagnostic hypothesis.



(FIGURE 1): Chest X-ray showing Damoiseau's parabola, indicating pleural effusion on the right.



(FIGURE 2): Axial CT scan of the lower chest, demonstrating dilatation of the inferior vena cava (in green) and pleural effusion on the right (blue arrowhead).



(FIGURE 3): Axial CT scan of the upper abdomen, demonstrating ascites (yellow arrow) and cirrhotic liver (purple line).

FINAL CONSIDERATIONS

Thus, the case reports an important and unusual finding in patients with liver cirrhosis, with hepatic hydrothorax being a recurring complaint of the patient, which demonstrates the severity of the course of the disease and may prioritize her on the waiting list for liver transplantation and increased survival.

REFERENCES

1. Toro Rendón, Luis Guillermo, et al. "Hidrotórax hepático: Reporte de caso y revisión de la literatura." *Revista colombiana de Gastroenterología*. v. 28, n. 4, p. 352-358. 2013.
2. Isberner RK, Couto CAS, Scolaro BL, Pereira GB, Oliveira R. Tricobezoar gástrico gigante: relato de caso e revisão da literatura. *Radiol Bras*. V. 28, n. 1. 2010.
3. Garbuzenko DV, Arefyev NO. Hepatic hydrothorax: an update and review of the literature. *World journal of hepatology*, v.9, n. 31, p. 1197, 2017.
4. García N, Mihas A. Hepatic hydrothorax. *J Clin Gastroenterol* 2004, 38:52-58.
5. Kinasewitz G, Keddissini J. Hepatic hydrothorax. *Current Opin- ion in pulmonary Medicine* 2003, 9:261-265.
6. Lazaridis KN, Frank JW, Krowka MJ, et al. Hepatic hydrothorax: pathogenesis, diagnosis, and management. *Am J Med*. 1999;107:262-7.
7. Roussos A, Philippou N, Mantzaris GJ, et al. Hepatic hydrothorax: pathophysiology diagnosis and management. *J Gastroenterol Hepatol*. 2007;22:1388-93.
8. Barreales M, Sáenz-López S, y col. Hidrotórax hepático refrac- tario: tratamiento eficaz con octreótido. *Rev Esp Enferm Dig* 2005, 97(11):830-835.
9. Boyer T, Haskal J. American Association for the study of liver diseases practice guidelines: the role of transjugular intrahepatic portosystemic shunt creation in the Management of portal hiper- tensión. *J Vasc Interv Radiol* 2005,16:615-629.
10. Anshu R, Pusalatha S. Diagnosis of hepatic hydrothorax by Tc- 99m sulfur colloid peritoneal scintigraphy. *Clin Nucl Med* 2001, 26(10):888-889.