

## VIDEOLAPAROSCOPIC APPROACH TO LEFT ADRENAL TERATOMA: CASE REPORT

---

***Remer Cristina Cintra Duarte***

São José dos Campos – SP

<https://lattes.cnpq.br/9258320316631926>

***Débora Cohen Zaide***

Rio de Janeiro

<https://lattes.cnpq.br/1078520398577116>

***Bruno Monteiro de Carvalho***

Santarém - PA

<http://lattes.cnpq.br/3254823022861332>

***Aline Durão de Andrade Pequeno***

Rio de Janeiro

<http://lattes.cnpq.br/9825303351084755>

***Luana Poubel Marques da Silva***

Rio de Janeiro

<http://lattes.cnpq.br/6779414416369685>

***Bianca Ribas Lee Santana***

Barra do Piraí - RJ

<http://lattes.cnpq.br/6802697245465026>

***Lucas Marassi Theodoro Sousa Oliveira***

São Lourenço-MG

<https://lattes.cnpq.br/0632771759188549>

All content in this magazine is licensed under a Creative Commons Attribution License. Attribution-Non-Commercial-Non-Derivatives 4.0 International (CC BY-NC-ND 4.0).



**Abstract:** These are rare tumors, originating from germ cells, commonly found in young people and their main topography is the gonads. Most patients are asymptomatic. If present, they manifest clinically by compression of neighboring structures. Therefore, they are usually voluminous at the time of diagnosis. Preoperative diagnosis is challenging, as they can be confused with other adrenal tumors. The treatment of choice is surgical resection.

**Keywords:** Teratoma, adrenal teratoma, vide-olaparoscopic transperitoneal adrenalectomy.

## INTRODUCTION

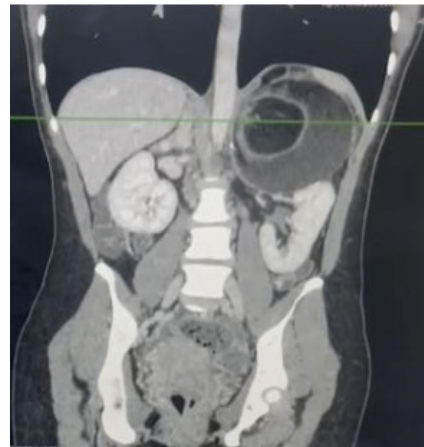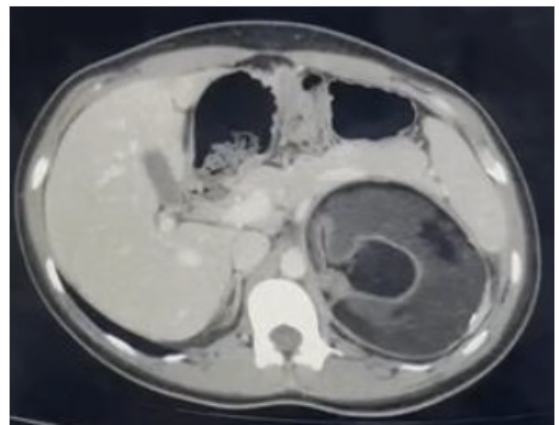
Teratomas are tumors originating from germ cells, most commonly found in young people, and their main location is the gonads. When retroperitoneal, they represent 4% of primary teratomas, and if in the adrenal glands, they are even rarer. They are classified as mature and immature according to their degree of cellular differentiation. Mature teratomas are predominantly composed of well-differentiated tissue, while immature teratomas are composed of undifferentiated tissue, which has a higher chance of malignant transformation. Preoperative diagnosis is challenging, as they can be confused with other adrenal tumors. The treatment of choice is surgical resection.

## METHOD MATERIALS

Female patient, 21 years old, with no family history and asymptomatic, having been diagnosed by incidental finding on imaging exam. Abdominal ultrasound showed a large, heterogeneous and hyperechoic expansile formation measuring approximately 9 cm located in the topography of the left adrenal gland with an aspect suggestive of a lesion with fatty/hematic content. Investigation continued with abdominal CT: expansive formation in the topography of the left

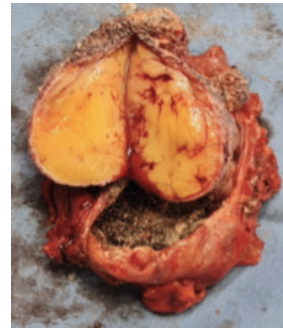adrenal gland measuring 97x98mm, with well-defined borders, parietal calcifications, heterogeneous content and fat density inside, without evidence of contrast enhancement, the appearance being compatible with a fatty lesion.

Normal laboratory tests including complete blood count, liver and kidney function, hormone levels, urinary catecholamines and metanephrine; urinary protein; urinary aldosterone; serum cortisol; plasma renin activity; serum dehydroepiandrosterone sulfate. Thus, the results excluded a functioning adrenal tumor.



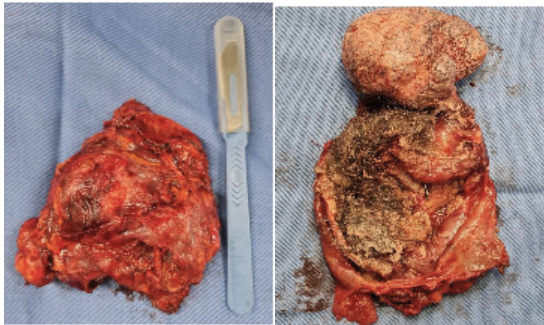
Figures 1 and 2: expansive formation in the topography of the left adrenal gland measuring 97x98mm, with well-defined limits, parietal calcifications, heterogeneous content and fat density inside, with no evidence of enhancement by contrast medium, the appearance being compatible with a fatty lineage lesion.

**Results:** The patient underwent videolaparoscopic transperitoneal adrenalectomy under general anesthesia in the right lateral decubitus position. The inventory revealed an adrenal tumor in close contact with the left renal vein and aorta. Left adrenalectomy was performed without complications. Macroscopic sections of the surgical specimen identified various tissues, such as hair and fat. The hypothesis of adrenal teratoma was raised, which was later confirmed by pathological anatomy. No immature tissue or malignancy was identified. The patient progressed well during hospitalization and was discharged on the second postoperative day and referred to the outpatient clinic.



## CONCLUSION

Teratomas are typically non-functioning tumors and their occurrence in adults and in adrenal topography is extremely rare. They are classically circumscribed masses with different densities due to the presence of multiple tissues, such as teeth, hair, bone, soft tissue and predominantly with fat density. Preoperative diagnosis is difficult even with computed tomography, the gold standard examination. Surgical approach for adrenal tumors > 4 cm is indicated and has a good postoperative prognosis.



## REFERENCES

Bahrami A, Ro JY, Ayala AG. An overview of testicular germ cell tumors. Archives of pathology & laboratory medicine [Internet]. 2007 Aug;131(8):1267-80. Available from: <http://www.ncbi.nlm.nih.gov/pubmed/17683189>

<http://www.ncbi.nlm.nih.gov/pubmed/17683189>

Peyvandi H, Arsan F, Alipour-Faz A, Yousefi M. Primary retroperitoneal mature cystic teratoma in an adult: A case report. Int J Surg Case Rep. 2016;28:285-288. doi: 10.1016/j.ijscr.2016.10.011. Epub 2016 Oct 11. PMID: 27769025; PMCID: PMC5072139.

Bellin MF, Duron JJ, Curet P, Dion-Voirin E, Grellet J. Primary retroperitoneal teratoma in the adult: correlation of MRI features with CT and pathology. Magn Reson Imaging. 1991;9:263-6.

Chong HMD, Lee FYJ, Lo A, Li CMJ. A giant gas-filled abdominal mass in an elderly female: a case report. World journal of gastroenterology?: WJG [Internet]. 2011 Aug 21 [cited 2012 Sep 30];17(31):3659-62. Available from: <http://www.pubmedcentral.nih.gov/articlerender.fcgi?artid=3180025&tool=pmcentrez&rendertype=abstract>

<http://www.pubmedcentral.nih.gov/articlerender.fcgi?artid=3180025&tool=pmcentrez&rendertype=abstract>

Davidson AJ, Hartman DS, Goldman SM. Mature teratoma of the retroperitoneum: radiologic, pathologic, and clinical correlation. Radiology. 1999;172:421-5.