

SHONE SYNDROME: A COMPLEX AND RARE CONGENITAL HEART DISEASE

Nicole Guenim Alé

Surgeon at `Pontificia Universidad Católica de Chile`

Camila Frugone

Pediatrician at: `Pontificia Universidad Católica de Chile` and resident of the pediatric unit of `Hospital Sótero del Río`

All content in this magazine is licensed under a Creative Commons Attribution License. Attribution-Non-Commercial-Non-Derivatives 4.0 International (CC BY-NC-ND 4.0).



Abstract: Shone syndrome is a rare congenital heart disease characterized by a combination of left ventricular outflow tract (LVOT) obstructions. It encompasses a spectrum of obstructive lesions that include supralvalvular mitral annulus, mitral valve stenosis, aortic coarctation, and subaortic stenosis. This heart disease is diagnosed during childhood, the symptoms appear early and include dyspnea, fatigue, paleness, feeding problems, etc. Information on its epidemiology is limited due to its rarity and lack of studies; however, it constitutes a relevant disease due to its potentially fatal effects in the pediatric population. In this work, the case of a 2-month-old infant is presented; Full term newborn (FTN) of a controlled pregnancy and without morphological anomalies described in prenatal ultrasounds. After delivery, the patient progressed favorably and was transferred to the postpartum period, where the physical examination revealed a systolic ejective murmur, with no other alterations. It was decided to study with an electrocardiogram, pressure in four extremities and an echocardiogram. The latter showed aortic coarctation, hypoplasia of the aortic arch, aortic valve stenosis, mild mitral valve stenosis and insufficiency, and a wide muscular ventricular septal defect (VSD). Thus, configuring the diagnosis of Shone Syndrome and achieving a timely intervention. Initially, cardiosurgery is performed to repair the aortic arch and close the VSD, and then banding is installed on the pulmonary artery. In conclusion, Shone syndrome is a complex disease that primarily presents with LVOT. Early diagnosis and appropriate treatment strategies are critical to improving patient outcomes. This work serves as a resource

for health professionals to consider Shone Syndrome within differential diagnoses and to motivate research and improve knowledge about this rare heart condition.

Keywords: Congenital heart disease, Shone syndrome, LVOT, Cardiosurgery

INTRODUCTION TO THE CASE

Shone syndrome is a very low prevalence congenital heart disease. It was defined for the first time in 1963 and currently accounts for 0.6% of all congenital heart diseases¹, registering at <1/1,000,000 inhabitants worldwide². It is characterized by a combination of left ventricular outflow tract (LVOT) obstructions that include a supralvalvular mitral annulus, mitral valve stenosis, aortic coarctation, and subaortic stenosis. It is referred as complete syndrome when all the aforementioned alterations are present, and an incomplete syndrome when 2 or 3 of the alterations are present.

CASE DESCRIPTION

FTN, 39 weeks gestational age, with appropriate weight, male. Controlled pregnancy, without pathologies or prenatal diagnoses. He had a normal delivery without complications and was sent to the puerperium with his mother. On the second day of life, respiratory distress was detected after feeding and a V/VI systolic murmur was heard during the physical examination.

He was hospitalized for a complete cardiological study, highlighting blood pressure in 4 extremities without significant differences and an echocardiogram with a finding of aortic arch hypoplasia with probable juxtaductal critical aortic coarctation, aortic valve stenosis, wide posterior muscular VSD,

1. Ganju, N. K., Kandoria, A., Thakur, S., & Ganju, S. A. (2016). A Constellation of Cardiac Anomalies: Beyond Shone's Complex. *Heart views: the official journal of the Gulf Heart Association*, 17(1), 23–26. <https://doi.org/10.4103/1995-705X.182643>

2. INSERM US14 -- TODOS LOS DERECHOS RESERVADOS. (s/f). Orphanet: Complejo de Shone. Orpha.net. Retrieved on July 22, 2023, de https://www.orpha.net/consor/cgi-bin/OC_Exp.php?lng=ES&Expert=99063

patent foramen ovale (PFO) and small patent ductus arteriosus (PDA).

Prostaglandins are started at a dose of 0.02 ug/kg/min, with readjustment according to PDA size by echocardiogram, which are maintained until evaluation and surgical resolution.

Cardiac surgery was performed with repair of the aortic arch with a chromatrix patch, attempted VSD closure with a Dacron patch, and ASD calibration. Postoperative control with echocardiography revealed a displaced VSD patch and an interventricular septum with a wide defect with exclusive left-to-right flow. In this context, it was decided to perform PA Banding, with the objective of redistributing the blood pumped by the heart to the systemic territory. He is progressing post-surgery in good condition and there is a plan to evaluate definitive VSD closure in 6 months after the first cardiosurgery.

DISCUSSION OF THE CASE

Unlike other heart diseases, the obstructive lesions of Shone Syndrome tend to worsen over time. The severity of mitral obstruction is the most significant indicator of survival and long-term prognosis. This is why early diagnosis and intervention allows the repair of injuries before the obstruction progresses, thus improving the patient's outcomes.

Furthermore, it is postulated that the diagnosis of aortic coarctation or mitral valve alterations must raise suspicion of other associated cardiac defects, since these two anomalies occur together in 20-59% of cases³, while the supralvalvular mitral annulus is associated with other defects in almost 90% of cases.

This anatomical alteration requires a surgical approach that seeks to correct the defects before the development of pulmonary hypertension. It is generally carried out in stages and must be adjusted to the particularities of each case, always with the objective of redistributing the flow to the systemic territory by reducing resistance in the LV outflow tract.

RELEVANCE AND CONCLUSION

Shone syndrome is one of the many congenital heart diseases that occur at a pediatric age, it encompasses multiple alterations that converge in LVOT.

During the neonatal period, it is essential that both the pediatrician and the general practitioner have a strong clinical consideration regarding non-specific symptoms, such as difficulty feeding, poor weight gain or heart murmurs, so that the necessary study to establish the diagnosis is requested early.

Furthermore, it is important to know the association between cardiac anomalies, so that when one is found in an echocardiogram, a direct search is made for other lesions that can lead to the configuration of a complete or incomplete syndrome.

Each of the previously discussed aspects become increasingly pertinent in Shone Syndrome, given that diagnosis and early intervention favor the prognosis and survival of the patient.

3. Ganju, N. K., Kandoria, A., Thakur, S., & Ganju, S. A. (2016). A Constellation of Cardiac Anomalies: Beyond Shone's Complex. *Heart views: the official journal of the Gulf Heart Association*, 17(1), 23–26. <https://doi.org/10.4103/1995-705X.182643>

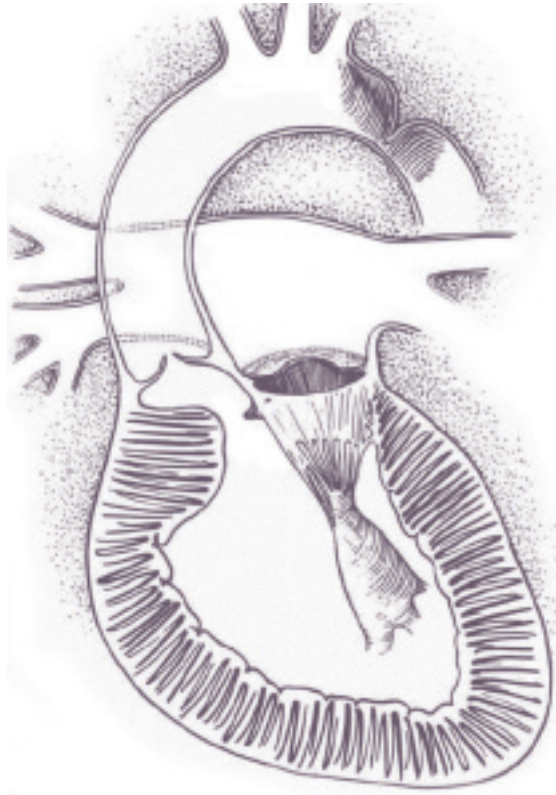


Image courtesy of Shone, JD., Sellers, RD., Anderson, RC., Adams, P., Lillehei, CW., Edwards, J. The developmental complex of "parachute mitral valve," supralvalvar mitral ring of left atrium, subaortic stenosis and coarctation of aorta. *American Journal of Cardiology*. 1963;11:714