

# LIVER METASTASECTOMY IN METASTATIC BREAST CANCER: REPORT OF TWO CASES AND LITERATURE REVIEW

*Data de aceite: 01/12/2023*

### **Rafael Martins Steffen**

Graduação em medicina – Faculdade de Medicina do ABC (2011)  
Residência em Cirurgia Geral – Faculdade de Medicina do ABC (2015)  
Residência Médica em Cirurgia Oncológica no A.C. Camargo (2018)  
São Paulo – SP  
<http://lattes.cnpq.br/0903869565049453>

### **Arthur Fernandes Pacheco**

Graduação em medicina – Fundação Técnico Educacional Souza Marques – Escola de Medicina (2011)  
Residência Médica em Cirurgia Geral – Hospital Estadual Getúlio Vargas (2015)  
Residência Médica em Cirurgia Oncológica no A.C. Camargo (2018)  
São Paulo – SP

### **Gabriela Camila Teixeira**

Graduação em medicina – Faculdade de Medicina do ABC (2019)  
Residência em Cirurgia Geral – Faculdade de Medicina do ABC (2022)  
São Paulo – SP

### **Bruna Alejandra Orellana Santos**

Graduação em medicina – Faculdade de Medicina do ABC (2021)  
São Paulo – SP

### **Marina Quaglio Oinegue Fulfaro**

Graduação em medicina – Faculdade de Medicina do ABC (2021)  
São Paulo – SP

**ABSTRACT:** Breast cancer is the most frequent neoplasm in women, with only 22% 5-year survival in metastatic disease. The hepatic metastasectomy, when eligible, showed an impact of 82 months on overall survival in patients submitted to the procedure. However, it is an alternative treatment still debatable in literature. In this study, two reports of metastatic breast cancer with surgical approach are discussed. Patient 1 had liver metastasis of initially triple negative invasive ductal breast carcinoma, but with metastatic immunohistochemistry HER-2 positive. Patient 2 presented hepatic metastasis of invasive ductal carcinoma luminal A, with immunohistochemistry compatible. Both patients underwent segmental hepatectomy associated with systemic chemotherapy. The reports presented reproduce favorable scenarios for metastasectomy, with good outcome of patients. The literature review, associated with the data from the reports,

demonstrate a significant impact on overall survival when a surgical approach was performed.

**RESUMO:** O câncer de mama é a neoplasia mais frequente em mulheres, sendo que a doença metastática apresenta sobrevida de apenas 22% em 5 anos. A metastasectomia hepática, quando passível de ser realizada, demonstrou impacto na sobrevida global média em 82 meses em pacientes elegíveis ao procedimento. No entanto, ainda é uma alternativa de tratamento pouco abordada na literatura. Neste estudo, serão relatados dois casos de câncer de mama metastático com abordagem cirúrgica. Paciente 1 apresentou metástase hepática de carcinoma de mama ductal invasivo inicialmente triplo negativo, porém com imuno-histoquímica de lesão metastática HER-2 positivo. Paciente 2 apresentou metástase hepática de carcinoma ductal invasivo luminal A, com imunohistoquímica compatível com a neoplasia de origem. Ambas as pacientes foram submetidas à hepatectomia segmentar associada à quimioterapia sistêmica. Os relatos apresentados reproduzem cenários favoráveis para a metastasectomia, com boa evolução das pacientes. A revisão literária citada, associada aos dados dos relatos, demonstram um impacto significativo na sobrevida global quando realizada a ressecção cirúrgica da metástase.

## INTRODUCTION

Breast cancer is one of the leading causes of death from neoplasia in the world and is the main type of neoplasm in women, with an estimated incidence rate of 29.7% in Brazil in 2020 (6). According to the American Breast Cancer Society there is an overall 5-year survival of approximately 22% in stage IV breast cancer. (20)

In cases of advanced disease, approximately 5 to 12% present isolated metastatic lesions, with survival rates of less than six months (3). The conventional treatment consists of chemotherapy or systemic hormone therapy, with no intention of cure in the majority of them. However, in some reserved cases, the resection of secondary implants is performed. (7) (2)

Patients with good liver function, low volume of metastatic disease, a limited number of up to five lesions and susceptible to a resection with free margins are considered eligible for liver metastasectomy, preferably by minimally invasive approach; after a complete resection of the primary tumor. (19) (4) (7). In addition, the disease-free interval longer than six months between the primary tumor and the diagnosis of metastasis is a better prognostic factor. (10)

Around 50% of metastatic breast cancer patients have implants in the liver, usually with later development at diagnosis (2). Liver dissemination is associated with worse evolution and when compared to other sites, such as bones and soft tissues, has a worse prognosis. (12)

According to the literature, treatment with exclusive chemotherapy in metastatic breast cancer for the liver presented an average survival rate of 18 to 24 months. (3) (4) However, for patients who had eligibility criteria for the surgical approach, the mean overall

survival was 82 months. (3)

Although there is still a lack of randomized studies with a large number of patients, reports with liver metastasectomy of secondary lesions from a primary breast cancer are found in literature. Disease-free survival was observed for a considerable time, directly impacting on the quality of life of patients, decreasing toxicity and adverse effects of pharmacological therapy. (11) (1) (2) (3) (4) (5) (14)

Two cases of surgical treatment of liver metastases in primary breast cancer are presented in this study, with a review of the current literature on the subject. Both cases were followed at the Surgical Oncology service of the Hospital de Clínicas de São Bernardo do Campo, SP, Brazil.

## CASES REPORT

**Case 1** - A 46-year-old female patient was diagnosed with triple negative invasive ductal cancer. Performed four cycles of neoadjuvance with Anthracycline, Cyclophosphamide and Taxane (AC + T). Subsequently, she underwent mastectomy with lymphadenectomy level I and II, on September 20, 2017. After surgical treatment, she underwent adjuvance with radiotherapy in the left breast. The pathological analysis showed invasive ductal carcinoma with metastasis in one of the 13 lymph nodes removed (ypT3N1(1/13)M0), with a free margin resection. Immunohistochemistry showed triple negative tumor for progesterone, estrogen and c-erbB-2 receptors.

During oncological follow-up, one year after the end of treatment, in October 2018, a single hepatic recurrence was diagnosed. Magnetic resonance imaging of the abdomen showed an heterogeneous nodular image in segment II of the liver, suggestive of metastatic lesion (Figure 1). On 16/01/2019, a PET-SCAN (Figure 2) was performed, revealing an hypodense hepatic hypermetabolic image measuring 3.4x2.9 cm in the left hepatic lobe SUV 8.5. A liver biopsy was performed, which confirmed metastatic disease and immunohistochemistry with estrogen-negative and progesterone and HER 2 positive receptors.

The patient underwent treatment with docetaxel and bevacizumab, in a total of four cycles. On May 28, 2019, she was submitted to a laparoscopic segmental hepatectomy. The anatomopathological study of the material, with dimensions 4.5 x 4.0 x 3.0 cm, confirmed infiltration of carcinoma with a distance of 0.1 cm from the nearest surgical margin. Immunohistochemistry from the hepatic lesion was her-2 receptor positive, besides the triple negative initial tumor; metastasis was reviewed and confirmed.

The patient followed treatment with dual blockade HER-2. Then, was submitted to adjuvant chemotherapy and hormonal targeting for her-2 metastatic disease with vinalrolbine, trastuzumab and pertuzumab.

In the follow-up, on 25/03/2020, a new Pet Scan was performed (Figure 3), which

showed no uptake.

Currently, the patient is in follow-up in the service, without evidence of recurrence.

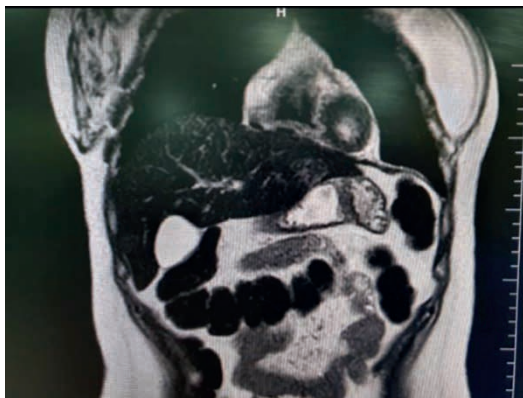


Figure 1. Magnetic resonance imaging with nodular heterogeneous image in segment II of the left lobe of the liver, suggestive of secondary neoplasia

Source: Compilation dand Rafael Martins Steffen

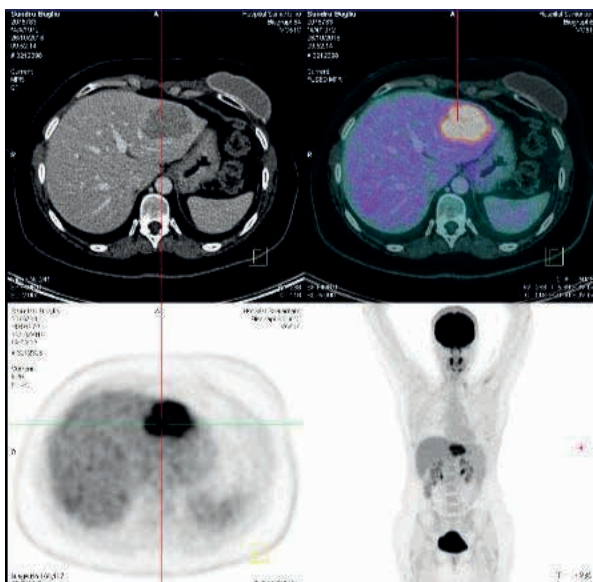


Figure 2. Image of hypodense area near the bloody edge of left partial hepatectomy, measuring 3.4x2.9cm, where previously there was hypodense liver injury

Source: Compilation dand Rafael Martins Steffen

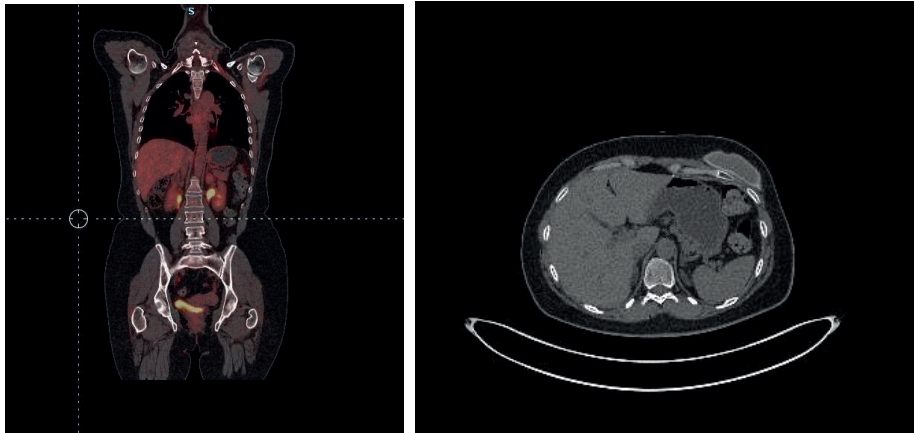


Figure 3. Absence of lesions with suspected glycolytic hypermetabolism for neoplastic involvement detectable to the Pet Scan method.

Source: Compilation dand Rafael Martins Steffen

**Case 2** - A 52-year-old female patient was diagnosed with invasive ductal carcinoma in the left breast in 2012. She underwent quadrantectomy and sentinel lymph node resection in August of the same year. The pathological analysis showed grade III invasive ductal carcinoma, measuring 3.6x3.0x2.6 cm, located at the intersection of the upper quadrant associated with intraductal carcinoma in rare spotlights, solid type of high grade, with free margins and negative sentinel lymph node (pT2N0/01M0). The immunohistochemistry showed immunoexpression for estrogen and progesterone receptors and negative for c-erbB-2 receptors, characterizing a luminal A tumor.

Then, the patient underwent six cycles of chemotherapy with docetaxel and doxorubicin and 30 sessions of radiotherapy. In addition, she underwent hormone therapy with tamoxifen for 2 years, which was later replaced by anastrozole.

During oncological follow-up, on October 2019, was submitted to an abdominal magnetic resonance imaging (Figure 1), showing a liver lesion of 2.1x3.0 cm. PET-SCAN was also requested (Figure 2), on 10/23/2019, which showed an hypermetabolic hepatic nodule in segment VIII of approximately 3.5 cm, suggestive of metastasis.

The patient underwent laparoscopic segmental hepatectomy in March 2020. The anatomopathological, a product of hepatectomy of dimensions 7.2x5.1x3.7 cm, showed a lesion measuring 4.4x4.0x3.3 cm, with a surgical margin compromised by the neoplasm. Immunohistochemistry was positive for estrogen and progesterone receptors, compatible with carcinoma of infiltrative breast origin. It was chosen to expand the margins in April 2020, with a new pathological analysis indicating absence of neoplasia in a surgical specimen.

Patient is now on follow-up with the oncology of the service, without evidence of recurrence.

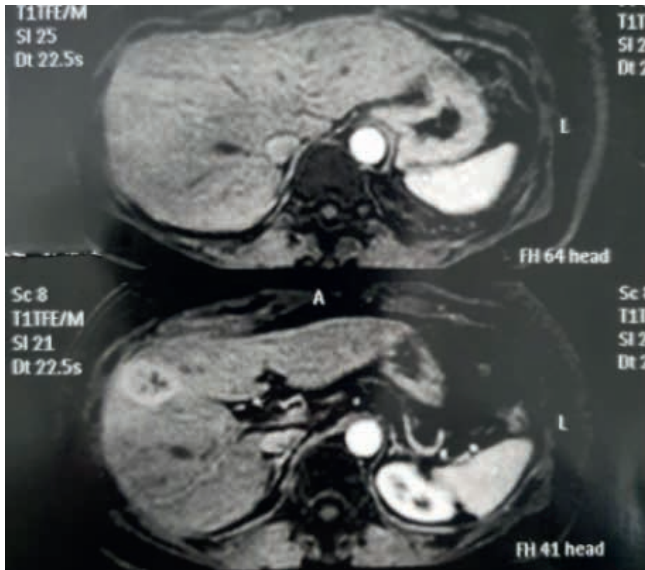


Figure 1. Liver of habitual morphology, showing nodule with heterogeneous signal and irregular vascularization involving segment VIII of its right lobe, demonstrating early enhancement in the arterial phase with tendency to central retention, measuring 2.1 x 3.0 cm in diameter.

Source: Compilation dand Rafael Martins Steffen

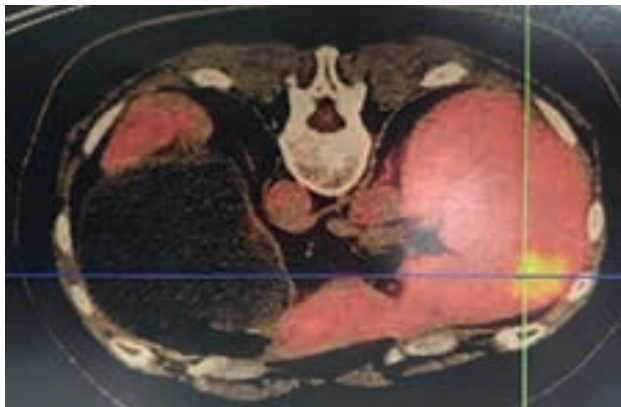


Figure 2. PET-SCAN with hypermetabolic hepatic nodule image in segment VIII, in the right lobe, approximately 3.5 cm, suggestive of secondary neoplastic process

Source: Compilation dand Rafael Martins Steffen

## DISCUSSION

To select patients candidates for the surgical approach, it is essential to analyze several factors, such as: characteristics of the primary tumor, degree of differentiation, absence of lymph node dissemination, metastatic initial stage, r0 resection of the primary and patient's performance status, among other factors. Thus, the group of eligible patients

is still very restricted, since approximately 9% of those with liver metastasis are susceptible to surgical approach by the eligibility criteria, which makes it challenging to choose the appropriate treatment. (1)

The reports presented reproduce favorable scenarios for hepatic metastasectomy. In both cases, the patients presented single liver injury, with no evidence of extrahepatic disease, preserved performance status and progression to metastasis after more than six months. These factors are considered as a good prognosis for the surgical approach, according to the literature presented in this study. (10) (3)

A study with 54 patients with metastatic breast cancer submitted to hepatectomy, with a single site of injury, demonstrated overall survival rates at 3 and 5 years after treatment of 50% and 34% (16). The study also evaluated that hormone receptors were factors for prognosis, with a relative risk of death 3.5 times higher in patients with negative receptors. The study concluded that hepatectomy is beneficent for selected patients with single liver metastasis, and that indications should be based on low surgical risk, probability of R0 resection, and patient performance status.(16)

In another multicenter study, patients who received exclusive chemotherapy versus surgical resection and chemotherapy were compared. Both groups had liver implants from a metastatic breast cancer that could be surgically treated. The overall survival was 80 months (95% CI 70-90 months); and the group with resection of the lesions had an average survival of 73 months, while the exclusive systemic treatment group had a survival of 13 months ( $p < 0.001$ ). (4)

A meta-analysis gathered studies to analyze the performance of hepatectomy in liver metastases of primary breast neoplasms. A total of 553 patients were analyzed, in whom metastasectomy was performed in women with controlled disease and exclusive hepatic site. The mean time to occurrence of hepatic dissemination was 40 months (CI 23-77). The mean overall survival was 40 months (CI 15-74) and there was 5-year survival in 40% of cases (CI 21-80%)(5) . Thus, it concluded that hepatectomy in metastatic breast neoplasia presented, had considerable 5-year survival for selected patients, with isolated liver injury and controlled extrahepatic disease. (5)

Also, the disease-free interval time of more than 6 months (between the end of treatment and the manifestation of a new neoplastic site), is an indication in literature of a better prognosis (11).

Thus, in the reports presented, patient 1 developed hepatic dissemination one year after the end of treatment, while patient 2 evolved with metastasis within five years of disease-free interval. These characteristics translate better prognosis and configure oligometastatic disease (11). The disease-free interval was longer than six months after the systemic treatment of the primary tumor, with good response.

In the first report, the patient presented immunohistochemistry of the primary tumor compatible with triple negative breast carcinoma. This subtype is associated with an



unfavorable prognosis in breast cancer, with a high resistance to radiation and a higher incidence of distant metastases. However, when hepatectomy surgical specimen was performed by a secondary metastatic site, metastasis was positive for HER2.

Recent studies showed that the immunohistochemical profile of metastases does not necessarily agree with the primary tumor. In approximately 10% of cases, divergences occur in the expression of HER2. (13) In addition, the heterogeneity of the tumor and the biological evolution can be different from the metastatic site. In these cases, the treatment protocol should be based on the characteristics of the secondary lesion, which confers a better prognosis (13).

It is also important to discuss the relevance of metastasectomy in the her2-positive patient scenario. According to the Cleopatra study, patients who used trastuzumab and docetaxel had noticeable improvement in prognosis with decreased progression or death and a 6.1-month increase in disease-free survival, treatment performed for the patient in question who had her2 positive. (9).

Recently, some studies have shown that absence of primary tumor lymph node involvement, isolated metastatic liver injury, and the development of effective therapies, such as the use of trastuzumab for HER2-positive tumors, were independent factors for an overall survival increase in cases of advanced breast tumors. (10)

## CONCLUSION

Although there are no specific guidelines that support the surgical approach of liver metastasis in breast cancer, there are reports and studies in the literature that show a benefit in such conduct. In specific cases, with disseminated disease restricted to the liver, metastasectomy with good surgical results can be performed. (5) (11)

The choice between systemic chemotherapy *versus* hepatectomy requires a critical analysis of each case. It is believed that there is a bias in the selection of patients, since, in order to fit the eligibility criteria for the surgical approach, the secondary lesion should present less aggressive behavior, and therefore, a better prognosis of the patient.

The analysis of overall disease survival when comparing the subgroups submitted to secondary lesion resection associated with systemic therapy *versus* exclusive systemic therapy treatment diverge in the literature.

However, there are no consistent studies evaluating disease-free survival time after resection of secondary implants, thus, needing a more rigorous evaluation in these cases.

In this study, two cases with favorable evolution of hepatic metastasis were reported. According to the literature, the surgical approach is feasible in specific cases, with restricted metastatic low volume disease and in patients with good performance status (10) (17), as occurred with the patients reported in this study. Currently, both are in oncological follow-up, with no evidence of disease recurrence.



Although hepatectomy is rare in the management of metastatic breast cancer for the liver, the studies described in this review indicate an increase in disease-free overall survival in patients selected for surgical approach. To evaluate the efficacy of such treatment, randomized studies are currently needed to better evaluate systemic chemotherapy *versus* systemic chemotherapy with hepatectomy.

## REFERENCES

- 1- Temukai, M., Hikino, H., Makino, Y. *et al.* Liver resection for HER2-enriched breast cancer metastasis: case report and review of the literature. *surg case rep* 3, 33 (2017). <https://doi.org/10.1186/s40792-017-0307-1>
- 2- Kalil, Antonio & Severa, Camila. Hepatectomy for liver metastases from breast cancer. *Revista do Colégio Brasileiro de Cirurgiões*, edition 32 (2005), pages 285-286. DOI: 10.1590/S0100-69912005000500014.
- 3- Bale R, Putzer D, Schullian P. Local Treatment of Breast Cancer Liver Metastasis. *Cancers*. 2019 Sep;11(9). DOI: 10.3390/cancers11091341.
- 4-Ruiz A, van Hillegersberg R, Siesling S, Castro-Benitez C, Sebah M, Wicherts DA, de Ligt KM, Goense L, Giacchetti S, Castaing D, Morère J, Adam R. Surgical resection versus systemic therapy for breast cancer liver metastases: Results of a European case matched comparison. *Eur J Cancer*. 2018 May;95:1-10. doi: 10.1016/j.ejca.2018.02.024. Epub 2018 Mar 23. PMID: 29579478.
- 5- Chua TC, Saxena A, Liauw W, Chu F, Morris DL. Hepatic resection for metastatic breast cancer: a systematic review. *Eur J Cancer*. 2011 Oct;47(15):2282-90. doi: 10.1016/j.ejca.2011.06.024. Epub 2011 Jul 7. PMID: 21741832.
- 6- National Cancer Institute; federal government; epidemiological data; records 2020; [http.: Reports - National Cancer Institute](http://reports.nationalcancerinstitute.gov/)
- 7- Cardoso F, Senkus E, Costa A, Papadopoulos E, Aapro M, André F, Harbeck N, Aguilar Lopez B, Barrios CH, Bergh J, Biganzoli L, Boers-Doets CB, Cardoso MJ, Carey LA, Cortés J, Curigliano G, Diéras V, El Saghir NS, Eniu A, Fallowfield L, Francis PA, Gelmon K, Johnston SRD, Kaufman B, Koppikar S, Krop IE, Mayer M, Nakigudde G, Offersen BV, Ohno S, Pagani O, Paluch-Shimon S, Penault-Llorca F, Prat A, Rugo HS, Sledge GW, Spence D, Thomssen C, Vorobiof DA, Xu B, Norton L, Winer EP. 4th ESO-ESMO International Consensus Guidelines for Advanced Breast Cancer (ABC 4)†. *Ann Oncol*. 2018 Aug 1;29(8):1634-1657. doi: 10.1093/annonc/mdy192. PMID: 30032243; PMCID: PMC7360146.
- 8- Swain SM, Kim SB, Cortés J, Ro J, Semiglazov V, Campone M, Ciruelos E, Ferrero JM, Schneeweiss A, Knott A, Clark E, Ross G, Benyunes MC, Baselga J. Pertuzumab, trastuzumab, and docetaxel for HER2-positive metastatic breast cancer (CLEOPATRA study): overall survival results from a randomised, double-blind, placebo-controlled, phase 3 study. *Lancet Oncol*. 2013 May;14(6):461-71. doi: 10.1016/S1470-2045(13)70130-X. Epub 2013 Apr 18. PMID: 23602601; PMCID: PMC4076842.
- 9- European Medicines Agency approves Perjeta for patients with metastatic breast cancer. Brazilian Society of Clinical Oncology (SBOC), São Paulo, March 18, 2013. Available in: <https://www.s boc.org.br/noticias/item/521-agencia-europeia-de-medicamentos-aprova-perjeta-para-pacientes-com-cancer-de-mama-metastatico>>.

- 10- Sadot E, Lee SY, Sofocleous CT, Solomon SB, Gönen M, Kingham TP, Allen PJ, DeMatteo RP, Jarnagin WR, Hudis CA, D'Angelica MI. Hepatic Resection or Ablation for Isolated Breast Cancer Liver Metastasis: A Case-control Study With Comparison to Medically Treated Patients. *Ann Surg*. 2016 Jul;264(1):147-154. doi: 10.1097/SLA.0000000000001371. PMID: 26445472; PMCID: PMC4818209.
- 11- Guckenberger M, Lievens Y, Bouma AB, Collette L, Dekker A, deSouza NM, Dingemans AC, Fournier B, Hurkmans C, Lecouvet FE, Meattini I, Méndez Romero A, Ricardi U, Russell NS, Schanne DH, Scorsetti M, Tombal B, Verellen D, Verfaillie C, Ost P. Characterisation and classification of oligometastatic disease: a European Society for Radiotherapy and Oncology and European Organisation for Research and Treatment of Cancer consensus recommendation. *Lancet Oncol*. 2020 Jan;21(1):e18-e28. doi: 10.1016/S1470-2045(19)30718-1. PMID: 31908301.
- 12- Wapnir IL, Price KN, Anderson SJ, Robidoux A, Martín M, Nortier JWR, Paterson AHG, Rimawi MF, Láng I, Baena-Cañada JM, Thürlimann B, Mamounas EP, Geyer CE Jr, Gelber S, Coates AS, Gelber RD, Rastogi P, Regan MM, Wolmark N, Aebi S; International Breast Cancer Study Group; NRG Oncology, GEICAM Spanish Breast Cancer Group, BOOG Dutch Breast Cancer Trialists' Group; Breast International Group. Efficacy of Chemotherapy for ER-Negative and ER-Positive Isolated Locoregional Recurrence of Breast Cancer: Final Analysis of the CALOR Trial. *J Clin Oncol*. 2018 Apr 10;36(11):1073-1079. doi: 10.1200/JCO.2017.76.5719. Epub 2018 Feb 14. PMID: 29443653; PMCID: PMC5891132.
- 13- Van Poznak C, Somerfield MR, Bast RC, Cristofanilli M, Goetz MP, Gonzalez-Angulo AM, Hicks DG, Hill EG, Liu MC, Lucas W, Mayer IA, Mennel RG, Symmans WF, Hayes DF, Harris LN. Use of Biomarkers to Guide Decisions on Systemic Therapy for Women With Metastatic Breast Cancer: American Society of Clinical Oncology Clinical Practice Guideline. *J Clin Oncol*. 2015 Aug 20;33(24):2695-704. doi: 10.1200/JCO.2015.61.1459. Epub 2015 Jul 20. PMID: 26195705; PMCID: PMC5478102.
- 14- Cady, B., Nathan, N.R., Michaelson, J.S. *et al.* Matched Pair Analyses of Stage IV Breast Cancer with or Without Resection of Primary Breast Site. *Ann Surg Oncol* 15, 3384–3395 (2008). <https://doi.org/10.1245/s10434-008-0085-x>
- 15- Badwe R, Hawaldar R, Nair N, Kaushik R, Parmar V, Siddique S, Budrukkar A, Mitra I, Gupta S. Locoregional treatment versus no treatment of the primary tumour in metastatic breast cancer: an open-label randomised controlled trial. *Lancet Oncol*. 2015 Oct;16(13):1380-8. doi: 10.1016/S1470-2045(15)00135-7. Epub 2015 Sep 9. PMID: 26363985.
- 16- Dominique Elias, Franck Maisonneite, Michel Druet-Cabanac, Jean-Francois Ouellet, Jean-Marc Guinebretiere, Marc Spielmann, Suzette Delalogue, An attempt to clarify indications for hepatectomy for liver metastases from breast cancer; *The American Journal of Surgery*, Volume 185, Issue 2, 2003, Pages 158-164, ISSN 0002-9610, [https://doi.org/10.1016/S0002-9610\(02\)01204-7](https://doi.org/10.1016/S0002-9610(02)01204-7).
- 17- Pagani O, Senkus E, Wood W, Colleoni M, Cufer T, Kyriakides S, Costa A, Winer EP, Cardoso F; ESO-MBC Task Force. International guidelines for management of metastatic breast cancer: can metastatic breast cancer be cured? *J Natl Cancer Inst*. 2010 Apr 7;102(7):456-63. doi: 10.1093/jnci/djq029. Epub 2010 Mar 10. PMID: 20220104; PMCID: PMC3298957.
- 18- Veltri A, Gazzera C, Barrera M, Busso M, Solitro F, Filippini C, Garetto I. Radiofrequency thermal ablation (RFA) of hepatic metastases (METS) from breast cancer (BC): an adjunctive tool in the multimodal treatment of advanced disease. *Radiol Med*. 2014 May;119(5):327-33. doi: 10.1007/s11547-013-0354-z. Epub 2013 Dec 3. PMID: 24297589.
- 19- Bale, Reto; Putzer, Daniel; Schullian, Peter. 2019. "Local Treatment of Breast Cancer Liver Metastasis" *Cancers* 11, no. 9: 1341. <https://doi.org/10.3390/cancers1109134>

20- National Cancer Institute; Surveillance and Epidemiology; Female Breast Cancer database; Division of Cancer Control; 2020. Available in: <https://www.breastcancer.org/symptoms/diagnosis/prognosis>.