

# POST-COVID CEREBRAL VENOUS THROMBOSIS COMPLICATED TO DURAL ARTERIOVENOUS FISTULA ASSOCIATED TO AUDIBLE PULSATILE TINNITUS WITHOUT STETHOSCOPE

*Data de aceite: 02/06/2023*

**Fabiola Gondim Medeiros Chaves**

Universidade Nilton Lins

**Daniel Ribeiro Chaves**

Hospital Adventista de Manaus

**Gisele Franco Castro**

Universidade Nilton Lins

**Daniel Oliveira Almeida**

Universidade Nilton Lins

**Diego Eduardo Nunes**

Universidade Nilton Lins

**Francisco Mauricio Maia Neto**

Universidade Nilton Lins

**Vicente Paulo Afonso Abreu**

Universidade Nilton Lins

**Amanda Souza Chaves Macedo**

Universidade Nilton Lins

**Clarice Lima**

Universidade Nilton Lins

associated to audible pulsatile tinnitus without stethoscope, based on recents publication regarding this matter.

## METHODS

Review of patient chart regularly monitored by the neurological service of Manaus Adventist Hospital.

Literature review about cerebral venous thrombosis complications; clinical manifestations and dural arteriovenous fistula treatment.

## RESULTS

Case report: A.O.S., 36-years-old, attended on 09/2020 with a complaint of intense left hemicranial headache for 01 week associated to nausea, dizziness and blurred vision. On 10/2020, after refractoriness to sintomatic treatment, a neuroimage identified cerebral venous thrombosis (CVT) in the superior sagittal sinus and partial in the transverse and sigmoid sinuses, greater on the left. The patient was treated with enoxaparin full anticoagulation and then

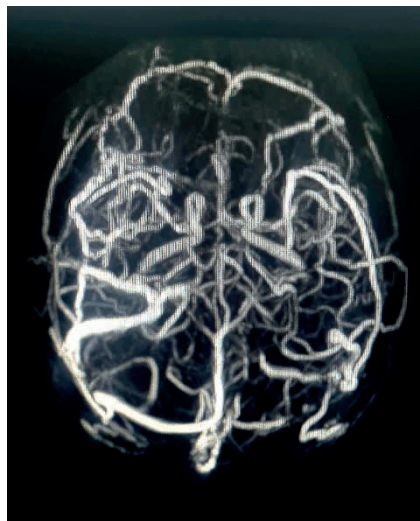
## PURPOSE

Present a clinical case report of post-covid cerebral venous thrombosis complicated to dural arteriovenous fistula

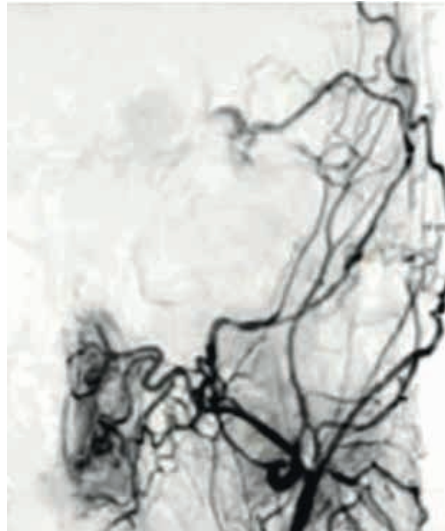
converted to warfarin for 6 months. An extensive laboratory etiological investigation was done but it's normal. He had history of Covid-19 infection two months ago. On 04/2021, an image control was performed and showed chronic CVT in the middle and posterior thirds of the superior sagittal sinus, and in the left transverse and sigmoid sinuses. On 07/2021, the case evolved to left pulsatile tinnitus that worsened when lying down, audible on ipsilateral periauricular auscultation and sometimes audible without a stethoscope aid. A new cerebral angiography was performed on 09/2021 and revealed a dural arteriovenous fistula (dAVF) in the sigmoid and left transverse sinuses. It was embolized on 11/2021, with tinnitus resolution. Discussion: dAVF can be congenital, idiopathic or acquired. When acquired, its main etiologies are traumatic brain injury, otomastoiditis, CVT, previous craniotomy and pregnancy. It is a rare complication of CVT, evolving in only 1% of cases. It is classified into low and high grade. Low-grade ones (Borden I; Cognard I and IIa) are usually not indicated for surgery, except in cases of secondary glaucoma, refractory orbital pain, and pulsatile tinnitus. High-grade ones (Borden II and III; Cognard IIb, IIa+b, III, IV and V) must be treated early due to of bleeding high risk. This case becomes particularly rare due to the high possibility of it has being triggered by the post-covid prothrombotic state.

## CONCLUSION

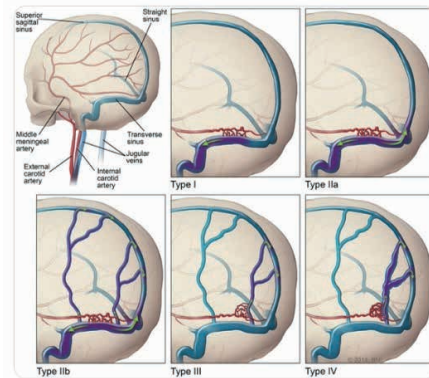
This is a case of CVT probably related to a post-covid prothrombotic state, which evolved after 10 months with dAVF associated to intense pulsatile tinnitus, resolved after embolization. The case deserves to be highlighted due to the rarity of its evolution, as well as the association with an unusual clinical sign of spontaneously audible pulsatile tinnitus, without a stethoscope aid.



Cerebral venous angiography resonance showing cerebral venous thrombosis in transverse and sigmoid sinuses on left side.



Cerebral arteriography showing dural arteriovenous fistula on left transverse and sigmoid sinus (Cognard I).



Cognard's dural arteriovenous fistulas classification.