

CAVECTOMY AND NEPHRECTOMY IN MONOBLOCK TO APPROACH LEIOMYOSARCOMA OF THE INFERIOR VENA CAVA: CASE REPORT

André Maciel da Silva

Service of General Surgery of the Hospital
Federal do Andaraí. Rio de Janeiro - RJ

Adriana de Freitas Fantinelli

Service of General Surgery of the Hospital
Federal do Andaraí. Rio de Janeiro - RJ

Priscila Fonseca de Sousa

Service of General Surgery of the Hospital
Federal do Andaraí. Rio de Janeiro - RJ

Pedro Henrique Salgado Rodrigues

Service of General Surgery of the Hospital
Federal do Andaraí. Rio de Janeiro - RJ

Rodrigo M. Japiassú Gonçalves

Service of General Surgery of the Hospital
Federal do Andaraí. Rio de Janeiro - RJ

All content in this magazine is licensed under a Creative Commons Attribution License. Attribution-Non-Commercial-Non-Derivatives 4.0 International (CC BY-NC-ND 4.0).



Abstract: With only 300 cases reported in the literature from 1871 onwards, leiomyosarcoma of the inferior vena cava continues to be classified as a very rare neoplasm. Only 2% of all leiomyosarcomas are vascular, with venous ones being five times more common.

Case clinical: A 49-year-old female patient, who underwent mastectomy in 2016 and 2018 (phylloides tumor), reports pain in the right flank, which radiated to the back and mesogastrium, which started in June 2021. CT of the abdomen and pelvis on 01/10/2022 with expansive formation, heterogeneous located in the right retroperitoneum, in the topography of the inferior vena cava and inseparable from the caudate lobe of the liver, the left renal vein and the right renal artery, measuring 5.8 x 4.5 cm. Planning: Prior venography was performed to identify vascular collateralization that would allow complete resection of the mass en bloc with the right kidney and right adrenal gland, without harming neighboring structures. After viewing the patency of the lumbar veins that supplied the left kidney in addition to the left vein (which would be sacrificed), surgery was indicated. Surgical technique: exploratory laparotomy was performed with identification of the mass adjacent to the right kidney, compatible with the inferior vena cava. Proximal and distal vascular control of the inferior vena cava was performed, the right renal and suprarenal vessels and the left renal vein were ligated. The piece was removed en bloc, with free macroscopic margins, without inserting a vascular prosthesis. During the postoperative period, the patient evolved uneventfully, with no impairment of her renal function at any time, and was discharged without any complications.

INTRODUCTION

Leiomyosarcoma was first described by Perl in 1871, and is the second most frequent

histological subtype among soft tissue sarcomas among adult patients. The vascular system is most commonly affected. In this case, the tumor arises from the tunica media of the vessel, and its location in the inferior vena cava (IVC) appears in 50% of these sarcomas. Although technically challenging for surgeons, cavectomy, when well planned and indicated, constitutes an important therapeutic resource for this neoplasm.

PRESENTATION OF THE CLINICAL CASE

A 49-year-old female patient, who underwent mastectomy in 2016 and 2018 (phylloides tumor), reports pain in the right flank, which radiated to the back and mesogastrium, which started in June 2021. Computed tomography of the abdomen and pelvis was performed on 01/10/2022, where an expansive, heterogeneous mass was observed, located in the right retroperitoneum, in the topography of the inferior vena cava. The tumor had indissociable limits of the caudate lobe of the liver, the left renal vein and the right renal artery, with dimensions of 5.8 x 4.5 cm. After performing venography to study vascular collateralization, we opted for exploratory laparotomy with a view to performing mass removal en bloc with the right kidney and right adrenal gland.

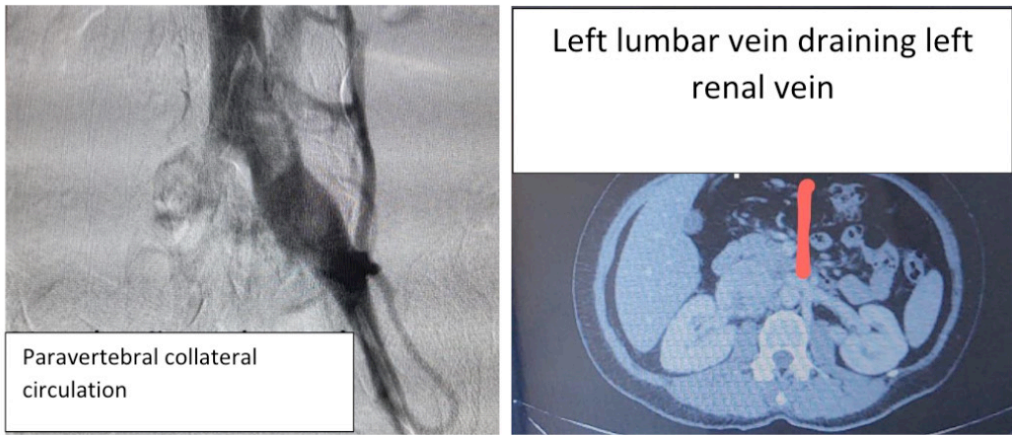


Figure 1: Planning steps: venography and computed tomography for visualization of collateral vasculature.

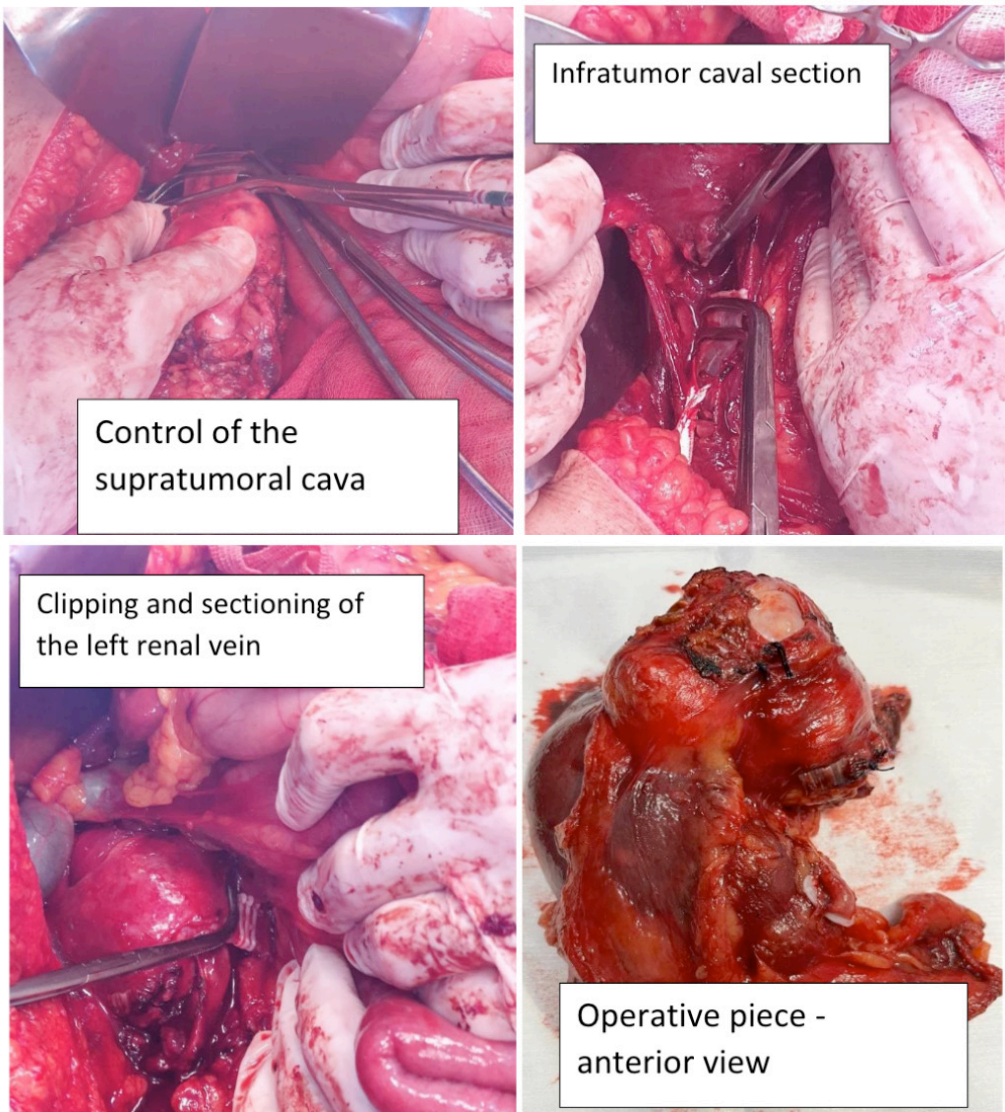


Figure 2: Surgical stage: vascular control and removal of the piece in one block

DISCUSSION

Leiomyosarcoma of the inferior vena cava usually has a poor prognosis. Tumor size is one of the main prognostic factors, and survival can range from 30 to 53% in five years in patients undergoing resection with free margins. These tumors have a slow growth pattern and, therefore, are usually diagnosed as large retroperitoneal masses, making curative resection a challenge for surgeons. The true IVC sarcoma derives from the smooth muscle cells of the vessel and its growth pattern can be intraluminal and/or extraluminal, and may involve neighboring structures.

In the case of inferior vena cava sarcoma, metastatic spread to the lungs is the most

common location. Resections of metastases, local recurrence, and adjuvant chemotherapy and/or radiotherapy must be considered in patients with long disease-free periods, good performance status, and limited disease. However, it is worth noting that there is no proven adjuvant benefit for this type of injury.

CONCLUSION

Although recurrence is common, there is no evidence of benefit from treatment with chemotherapy or radiotherapy for the treatment of leiomyosarcoma in this topography, with cavectomy, with adequate prior vascular study, being the best treatment option so far.

REFERENCES

- Fonseca MSM, Cardoso L, Lima GRA, Liberato AP, Silveira MC, Ramos LEL, et al. Leiomiiosarcoma de veia cava inferior: um relato de caso. *Rev Fac Ciênc Méd Sorocaba*. 2018;20(2):110-2. DOI: 10.23925/1984-4840.2018v20i2a11
- Lino Luis Sanches Larangeira, TCBC-PR1; Naja Nabut2; Alda L. Guembarovski3. Leiomiiosarcoma de veia cava inferior. *Rev. Col. Bras. Cir.* Vol. 33 - Nº 2, Mar. / Abr. 2006
- Dew J, Hansen K, Hammon J, McCoy T, Levine EA, Shen P. Leiomyosarcoma of the inferior vena cava: surgical management and clinical results. *Am Surg*. 2005;71(6):497-501.
- HOLLENBECK, ST.; GROBMYER, SR.; KENT, KC.; et al. Surgical treatment and outcomes of patients with primary inferior vena cava leiomyosarcoma, *J Am Coll Surg*. v.197, n.4, p.575-9, 2003.
- PERL, Leopold. Ein fall von sarkom der vena cava inferior. *Virchows Arch Pathol Anat*. v.53, p.378-83, 1871.
- KIM, JT.; KWON, T.; CHO, Y.; et al. Multidisciplinary treatment and long-term outcomes in six patients with leiomyosarcoma of the inferior vena cava. *J Korean Surg Soc*.v.82, n.2, p.101-9, 2