

## USEFULNESS OF SERIAL BIOPSIES IN PATIENTS UNDERGOING COLONOSCOPY IN THE VIEW OF THE ENDOSCOPIST IN RELATION TO THE REFERRING PHYSICIAN

---

***Rosival Vicente de Paula***

Endoscopy Department at Hospital Nove de Julho and Hospital Ipiranga  
São Paulo Brazil  
<https://orcid.org/0000-0003-1019-0189>

***Bruna Krubniki***

Endoscopy Department at Nove de Julho Hospital  
São Paulo Brazil  
<https://orcid.org/0000-0002-6734-5199>

***Thiago Camilo de Andrade Bertolotto***

Endoscopy Department at Nove de Julho Hospital  
São Paulo Brazil  
<https://orcid.org/0000-0002-5188-0111>

***Andressa Tomé Rezende de Faria***

Endoscopy Department at Hospital Nove de Julho  
São Paulo Brazil  
<https://orcid.org/0000-0002-1418-0861>

***Pedro Henrique Teles Prado***

Endoscopy Department at Hospital Nove de Julho and Hospital Ipiranga  
São Paulo Brazil  
<https://orcid.org/0000-0002-3979-1394>

All content in this magazine is licensed under a Creative Commons Attribution License. Attribution-Non-Commercial-Non-Derivatives 4.0 International (CC BY-NC-ND 4.0).



***Paula Cristina de Moraes Freitas***

Endoscopy Department at Hospital Nove de Julho  
São Paulo Brazil  
<https://orcid.org/0000-0003-1446-6461>

***Bruna Lemos Silva***

Endoscopy Department at Hospital Nove de Julho  
São Paulo Brazil  
<https://orcid.org/0000-0001-6830-0681>

***Morgana Andressa da Silva Santos***

Endoscopy Department at Hospital Nove de Julho  
São Paulo Brazil  
<https://orcid.org/0000-0003-3789-3191>

***Thiago Festa Secchi***

Hospital Nove de Julho  
<https://orcid.org/0000-0003-1818-6934>

**Abstract:** Colonoscopy is a diagnostic method used since 1970 that allows evaluation and screening of colorectal diseases. Patients with chronic diarrhea and normal mucosa on colonoscopy examination, serial biopsies can provide relevant information to aid in the diagnosis and appropriate treatment. In recent years, we have observed a significant increase in the number of requests for serial biopsies in colonoscopy. A total of 3,577 colonoscopic exams were performed from 01/01/2019 to 04/30/2021, with 298 (8.3%) colonoscopies with serial biopsies being performed, after exclusions we selected 222 patients and divided into two groups. In group I, 140 (63.1%) patients underwent serial biopsies at the request of the assistant physician, of whom 119 (85%) had no changes in the endoscopic examination, 83 (59%) had no histological changes. In group II, with 82 (36.9%) patients undergoing serial biopsies at the discretion of the endoscopist, of these 30 patients (37%) there were no endoscopic changes and in 19 (23%) there were no histological changes. In group II, the serial biopsies took into account the clinical context and the endoscopic findings, in view of which a greater number of alterations were found, both in the colonoscopic and histological findings. This demonstrates that the endoscopist's decision to perform serial biopsies during colonoscopy has a higher diagnostic yield.

**Keywords:** Colonoscopy; biopsies; chronic diarrhea;

## INTRODUCTION

Colonoscopy is a diagnostic method first used 1970 <sup>(1)</sup> and since then it has become a fundamental diagnostic method for the evaluation and screening of colorectal diseases such as: neoplasms, polyps, abdominal pain, digestive bleeding, constipation, unexplained iron deficiency anemia, inflammatory bowel disease, among others. On the other hand,

in patients with chronic diarrhea and normal mucosa on colonoscopy, serial biopsies can provide relevant information to aid in the diagnosis and appropriate treatment <sup>(2)</sup>.

In the study by Kagueyama et al, serial biopsies in patients with chronic diarrhea and normal colonoscopy identified alterations in almost 50% of the cases, and 22% could have their treatment modified after the identification of collagenous colitis, lymphocytic colitis or eosinophilic colitis<sup>(3)</sup>.

The recommendations of the Royal College of Pathologists that the yield of colonic biopsies have a positive predictive value and clinical value regarding their histopathology is essential for the selection of patients with the correct clinical context, with a history of persistent and bloodless diarrhea<sup>(4)</sup>.

In recent years, we have observed a significant increase in the number of requests for serial biopsies in colonoscopy. But is there any indication? How to proceed?

Our objective was to evaluate the diagnostic yield of serial colonic biopsies in the investigation of lower gastrointestinal symptoms based on the decision of the endoscopist or on the request of the patient's attending physician.

## METHODOLOGY

Retrospective, cross-sectional, descriptive study, with review of medical records, endoscopic and anatomopathological reports. Search in the endoscopic image storage system database (ENDOX® – TESI GROUP) with the keyword “serial biopsies” in the period from 01/01/2019 to 05/30/2022 in an endoscopy sector in the city of Sao Paulo.

Serial biopsies were collected in two random fragments per segment and separated into four vials: 1- terminal ileum; 2- cecum and ascending colon; 3- transverse and descending colon and 4- sigmoid colon and rectum.

Clinical Condition	Procedure
Microscopic Colitis	<b>At least 2 fragments of the segments:</b> ascending, transverse, descending and sigmoid colon. <b>OR</b> Three to four fragments: right colon and left colon
Assessment of inflammatory bowel disease activity	<b>At least two fragments from each segment:</b> ileum, ascending, transverse, descending, sigmoid, and rectum colon.
CRC screening in inflammatory bowel disease	Biopsies directed by conventional chromoscopy or digital chromoscopy. <b>OR</b> <b>Random biopsies:</b> <ul style="list-style-type: none"> <li>• <b>Pancolitis at diagnosis:</b> biopsies of the four quadrants every 10 cm of the entire colonic segments.</li> <li>• <b>Segmental colitis at diagnosis:</b> biopsies of the four quadrants every 10 cm of the involved segment.</li> </ul>
Pouchitis (bolsite)	Multiple biopsies of the pouch and afferent loop.
Graft versus host disease	<b>Retosigmoidoscopy:</b> <ul style="list-style-type: none"> <li>• At least 4 fragments from the rectum/sigmoid and 4 fragments from the descending colon.</li> </ul> <b>Ileocolonoscopy:</b> <ul style="list-style-type: none"> <li>• At least 4 fragments from each segment: terminal ileum, ascending colon, transverse colon, descending colon, and sigmoid colon and rectum.</li> </ul>

Table 1: Main indications for colonoscopy with serial biopsies <sup>(5,6)</sup>.

The reports and images of the colonoscopies and the results of histology were reviewed and patients who had altered bowel habits, chronic diarrhea, abdominal distension, abdominal pain and weight loss were selected.

We divided the patients into two groups, those undergoing serial biopsies at the request of the patient's attending physician (group I) and those undergoing serial biopsies at the discretion of the endoscopist (group II) based on the clinical context and endoscopic findings.

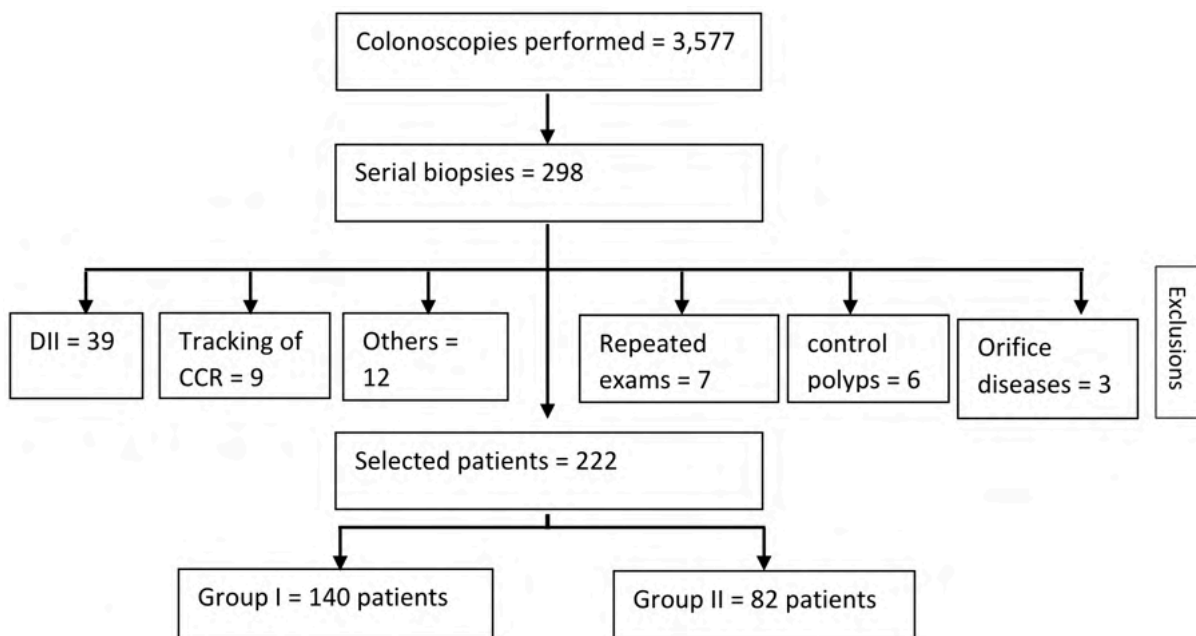
## RESULTS

A total of 3,577 colonoscopic exams were performed from 01/01/2019 to 04/30/2021, with 298 (8.3%) colonoscopies with serial biopsies being performed, we excluded: 7 patients with repeated exams and 69 with inflammatory bowel disease, control of

polyps and other previously known colitis or neoplasms during the analyzed period, at the end of the study 222 patients were selected (Table 2).

Overall, the mean age of patients was 38 years and the median was 36 years (18-68) and 56% of patients were female. In group I (patients who underwent serial biopsies at the request of the attending physician) 140 patients (63.1%) were selected, of which 119 (85%) had no changes in the endoscopic examination, 83 (59%) had no histological changes. In 36 (25%) patients, even with normal endoscopic findings, there were nonspecific histological changes (Table 3).

In group II (patients who underwent serial biopsies at the discretion of the endoscopist), 82 patients (36.9%) were selected. Of these 30 patients (37%) there were no endoscopic changes and in 19 (23%) there were no histological changes. On the other hand,



DII: inflammatory bowel disease; CCR: colorectal cancer; Others: hypovitaminosis, control of colitis, investigation of anemia and digestive bleeding.

Table 2: patient selection.

Colonoscopy and histology findings	Group I N=140	Group II N=82
Age (average) years	37	39
Age (median) years	35 (18-68)	38 (20-66)
Gender		
Feminine	83 (59%)	42 (51%)
Male	57 (41%)	40 (49%)
Normal colonoscopy	119 (85%)	30 (37%)
Abnormal colonoscopy	21 (15%)	52 (63%)
Normal histology	83 (59%)	19 (23%)
Normal histology	57 (41%)	63 (77%)
Normal colonoscopy and abnormal histology	36 (25%)	11 (13%)

Table 3: colonoscopic and histological findings in serial biopsies performed.

11 patients (13%) with normal endoscopic examination had nonspecific histological changes (Table 3).

In all patients, biopsies of the terminal ileum were performed, 201 (90.5%) had no changes. In 21 (9.5%) we found nonspecific ileitis at colonoscopy, and in 17 (7.6%) they had ileitis at colonoscopy and histology.

## DISCUSSION

The decision to perform colonoscopy with serial biopsies must take into account some aspects, among them: the available resources, the patient's clinic, the lack of response to the treatment of chronic diarrhea and endoscopic findings. <sup>(6,7)</sup> In group II, the serial biopsies took into account the clinical context and the endoscopic findings, in view of which a greater number of alterations were found, both in the colonoscopic and histological findings. This demonstrates that the endoscopist's decision to perform serial biopsies during colonoscopy has a higher diagnostic yield.

On the other hand, we found a considerable number of requests for serial biopsies, without any clinical criteria, such as: control or investigation of hemorrhoidal disease, anal pruritus, proctalgia, hypovitaminosis, constipation, investigation of anemia, routine colorectal cancer screening, polyps, among others. Such indications mentioned above do not bring benefits or additional information for the patient and, on the other hand, may even interfere with adequate clinical reasoning, generating a greater risk of iatrogenic diseases, in addition to increasing the examination time and costs for the health system.

Aiming to optimize health resources, the study by Peixoto et al, recommend that serial biopsies be performed in patients with suspected microscopic colitis, that is, those with chronic non-bloody watery diarrhea, nocturnal bowel movements, with or without weight loss, colonoscopy normal or near normal, unresponsive to conventional

symptomatic treatment, irritable bowel syndrome or celiac disease that do not have a clear diagnosis or do not respond to specific treatment, in addition to suspected or managed treatment of inflammatory bowel disease, pouchitis, and graft disease versus host<sup>(5)</sup>.

In all patients, ileal biopsies were performed, and nonspecific inflammatory changes were found in a minority of them. Terminal ileum biopsy is most useful in patients with suspected inflammatory diarrhea with a strong suspicion of Crohn's disease. We chose to exclude patients with

inflammatory bowel disease from this study, since in these cases serial biopsies must be considered both for initial diagnosis and to assess profound remission, defined by clinical, endoscopic and histological improvement<sup>(7,8,9)</sup>.

The main limitations of our study were the following: cross-sectional, retrospective, descriptive, single-center study with limited information described in the medical records of the patients analyzed due to the high turnover of the endoscopy service, therefore, more studies are needed to better evaluate the benefits of serial biopsies.

## REFERENCES

1. Nagasako K, Endo M, Takemoto T, et al. The insertion of fibercolonoscope into the cecum and direct observation of the ileocecal valve. *Endoscopy*. 1970; 2(2): 123.
2. Morarasu S, Haroon M, Morarasu BC, et al. Colon biopsies: benefit or burden? *Journal of Medicine and Life* Vol. 12, Issue 2, April-June 2019, pp. 156–159.
3. Kagueyama FMN, Nicoli FM, Bonatto MW and Orso IRB. Importance of biopsies and histological evaluation in patients with chronic diarrhea and normal colonoscopies *ABCD Arq Bras Cir Dig* 2014;27(3):184-187.
4. Howat A, Boyd K, Douce G. *Histopathology and cytopathology of limited or no clinical value*. The Royal College of Pathologists. 2 edicion. 2005; London: RCPPath
5. Peixoto A, Silva M, Pereira P, Macedo G. Biopsies in Gastrointestinal. *Endoscopy: When and How*. *GE Port J Gastroenterol*. 2016;23(1):19-27.
6. Bateman AC, Patel P. Lower gastrointestinal endoscopy:guidance on indications for biopsy. *Frontline Gastroenterology* 2014;5:96–102. doi:10.1136/flgastro-2013-100412
7. Guideline. The role of endoscopy in the management of patients with diarrhea. *Gastrointestinal Endoscopy*. Volume 71, No. 6 : 2010.
8. Melo MMC, Netinho JG. Endoscopic aspects in the diagnosis of terminal ileum diseases. *Rev. Col. Bras. Cir.* 37 (3)Jun 2010.
9. Giri S, Angadi S, Jearth V. Deep Remission in Crohn's Disease: Optional or Quintessential. *Clin Gastroenterol Hepatol*. 2021;S1542-3565(21)01355-0.