

**NEUROPSYCHIATRIC
COMPLICATIONS AFTER
COVID-19 INFECTION
AND IMPLICATIONS FOR
CLINICAL PRACTICE:
REPORT OF TWO CASES**

Vitória Palazoni Viegas Mendonça

Universidade Tiradentes, Aracaju

<http://lattes.cnpq.br/4970565582520646>

Helena Pinho de Sá

Universidade Federal de Sergipe, Aracaju

<http://lattes.cnpq.br/9841767889092695>

*Tássia Mayara Rodrigues Cardoso
Rollemberg*

Universidade Tiradentes, Aracaju

<http://lattes.cnpq.br/3873115326397532>

Maria Natália da Silva Montalvão

Universidade Tiradentes, Aracaju

<http://lattes.cnpq.br/4696373421780097>

Natália Palazoni Viegas Mendonça

Universidade Tiradentes, Aracaju

<http://lattes.cnpq.br/7507437081446460>

Bianca Mendonça Andrade

Universidade Tiradentes, Aracaju

<http://lattes.cnpq.br/5400225363192464>

Bárbara Palazoni Viegas Mendonça

Universidade Tiradentes, Aracaju

<http://lattes.cnpq.br/8692286661881269>

Lis Campos Ferreira

Universidade Tiradentes, Aracaju

<http://lattes.cnpq.br/5754047196028912>

All content in this magazine is licensed under a Creative Commons Attribution License. Attribution-Non-Commercial-Non-Derivatives 4.0 International (CC BY-NC-ND 4.0).



Abstract: Introduction: The pandemic of the new Corona Virus (SARS-CoV-2) has become a stressor factor in daily life worldwide, showing its deleterious influence on the mental and physical health of a large part of the population, through the effects of infection in the human body, a biopsychosocial being. Beforehand, this article reports two clinical cases of infection that progressed with neuropsychiatric alterations, evolving with a manic picture of presumed organic basis. **Case Report:** Case 1: Patient, 38 years old, was taken to hospital after 2 days of positive test for SARS-CoV 2, presenting episodes of paresthesia and muscle weakness. MRI evidenced diffuse ischemic areas, being carried out successive therapies with corticosteroids, anticoagulation and immunobiological. Next, she presents with persistent mental status alterations such as racing thoughts and grandiose content logorrhea, increased libido, and expansive and hostile moods. Case 2: patient, 56 years old, RT-PCR positive for COVID-19, without alterations in neuroimaging tests, treated with Dexamethasone, Azithromycin and Dipyrone. She evolved with behavioral and mood alterations and mystical-religious delusions. After therapy with antipsychotics and mood stabilizers, patients evolved with gradual improvement in symptoms. **Discussion:** Association of neuropsychiatric symptoms present in 22.5% of patients infected with COVID-19 was demonstrated. The most common neurological manifestations include headaches and sound disorders, as well as encephalopathy. The psychiatric manifestations include anxiety and other related disorders. Two main pathophysiological mechanisms have been described: (a) direct brain injury due to the virus and/or (b) secondary injury to the immune response to the virus; it also gives possibility of adverse neuropsychiatric effects

related to the treatment for the condition. **Conclusion:** It is assumed that the viral infection by SARS-CoV-2 and the medication treatment may be associated with the neuropsychiatric manifestations evidenced in the reported cases. It is uncertain that the symptoms will recur in the long term, or that requires further investigation and clinical follow-up.

Keywords: COVID-19, Neurobehavioral manifestations, Neuropsychiatry.

INTRODUCTION

The new Corona Virus (SARS-CoV-2) pandemic has become a stressor factor in daily life worldwide. The pandemic showed its deleterious influence on the mental and physical health of a large part of the population, both indirectly and directly, through the effects of infection in the human organism, a biopsychosocial being.

According to the specialized bibliography, during previous pandemics, a higher level of neuropsychic disease was perceived than normal both in the general population and among those cured of pandemic cases and health professionals. In March 2020, a national survey conducted in the United States showed that 40% of the American population reported prejudice in daily life due to the pandemic. Furthermore, a significant correlation was demonstrated between the presence of anxiety symptoms and the difficulty of coping with the COVID-19 pandemic. Social distance, interruption of services and care, and unemployment are some of the factors that could justify such findings.

Various reports and series of cases published in the first year of the pandemic demonstrate that COVID-19 symptoms can present with neurological alterations (such as dullness, headache, among others) as well as psychiatric alterations, leading to phobic-

anxious, depressive, manic symptoms, psychotic and post-traumatic stress. There is still an increase in the prevalence of psychic symptoms, both in health professionals (without a diagnosis of mental disorder), and in patients already diagnosed.

Among the various diagnoses, we found Bipolar Disorder Due to Other Medical Conditions. Cerebrovascular lesions, of the ischemic variety, may be one of the etiological causes for such a neuropsychiatric complication, which may manifest as a mania. In these cases, patients present a persistent period of high and expansive mood, with euphoria, grandiose ideas, increased psychomotricity and sexual libido, decreased need for sleep and appetite, impulsive behaviors, irritability or heteroaggression, and that arise chronologically related to a basic clinical event, with evidence that the disorder is a direct physiological consequence of another medical condition, not better explained by a mental disorder. The disorder causes significant prejudice, social or professional dysfunction, and may require hospitalization to prevent harm to oneself or others.

This article reports two clinical cases of SARS-CoV-2 infection that presented neuropsychiatric alterations with manic conditions of presumed cerebrovascular etiology, in patients with no prior psychopathological history.

CASE REPORT

CASE 1

Female patient, 38 years old, with a history of cerebral venous thrombosis for 2 years, stable, with sequelae, with a family history of anxiety disorder, refusal to use psychoactive substances or smoking. Two days after being tested positive for SARS-CoV 2, she was taken to the hospital with episodes of paresthesias in left dimidium, and was then referred

for hospital admission. Magnetic resonance imaging (MRI) of the brain (Figure 1) and angiography of the brain were performed, which showed cortical ischemic foci and filament with a reduction in the number of small peripheral arterial branches, therefore treating a picture suggestive of central nervous system vasculitis. After pulse therapy with Methylprednisolone 1g/day for 05 days, she presented improvement and was discharged from the hospital. The day after discharge, however, she presented a new episode of motor failure to the left, with a new MRI of the skull with the presence of new ischemic lesions affecting different areas. Considered in retrospect to the treatment initially intended, oral corticosteroid therapy with Prednisone 1mg/kg/day, anticoagulation and human immunoglobulin 400 mg/kg/day for 5 days was introduced. After a week, the patient was submitted to control neuroimaging and a new brain injury was evidenced, being opted for treatment with Rituximabe. The patient was discharged with almost complete neurological recovery, with only slight distal weakness remaining in the left upper limb.

On mental status examination, she presented alterations after 26 days of RT-PCR positive for COVID-19, such as irritability, emotional lability, expansive and hostile mood, decreased need for sound, accelerated thinking, and speechlessness of grandiose content. She did not accept the care of the nursing team, referring that she would instruct to adequately sanitize the objects, claiming to work without monitoring the institution's surveillance, configuring delusions of grandeur. She also began to show increased libido, going on to exhibit disinhibited and seductive behavior towards health professionals in front of her spouse. There was no evidence of presence of hallucinations.

DISCUSSION

Both reports present neuropsychiatric alterations associated with SARS-CoV-2 infection. The availability of pre-infection images reduces the probability of risk factors, such as previous ischemic lesions, being confused as health effects. Also, it is understood that when an individual is affected by a disease, apart from pathophysiological alterations, social and emotional changes occur. Because she is experiencing a new moment, the patient can develop psychological effects that alter his habitual behavior.

Association of neuropsychiatric symptoms present in 22.5% of the patients infected with COVID-19 was demonstrated. The most common neurological manifestations included headache (3.7%) and sleeping disorders (3.4%), along with encephalopathy (2.3%), myalgia (2.0%) and pain (1.8%). The most common psychiatric manifestations included anxiety and other related disorders (4.6%). Neurological manifestations have been described in almost half of those with severe infection. In a study carried out in the United Kingdom, of 125 patients with neurological or neuropsychiatric alterations, 62% presented cerebrovascular event, of which 74% suffered ischemic stroke, 12% intracerebral hemorrhage, and 1% CNS vasculitis.

Potential mechanisms for the neuropsychiatric manifestations related to SARS-CoV-2 have been proposed, which may arise in the context of acute or later viral infection. Two main pathophysiological mechanisms have been described: (a) direct brain injury due to the virus and/or (b) secondary injury to the immune response to the virus. Increased production of inflammatory cytokines can lead to endothelial injury or result in a hypercoagulable state, which can lead

Due to manic symptoms with psychotic symptoms, Risperidone 2 mg every 12/12 hours, Valproic acid 500 mg every 12/12 hours and Alprazolam 1 mg at night were started. The patient evolved with gradual improvement of the mental symptoms and or complete weaning from the medications occurred in two months.

CASE 2

Female patient, 56 years old, with a history of systemic arterial hypertension, without a personal or family history of mental disorders, denied use of psychoactive substances and tobacco. She performed positive RT-PCR for COVID-19, presenting only mild flu symptoms and pain in the left lower limb. She had an evaluation with a neurologist and neuroimaging tests that did not show any alterations, being treated with symptomatic drugs, including azithromycin, dipyron and dexamethasone.

After the episode, the patient evolved with behavioral and mood alterations, accelerated compensation, logorrhea, expansive mood, irritability, significant emotional lability in short intervals of time, with grandiose ideas and mystical-religious delusions. She credited being an envoy of God to found a new religion on Earth and with the power to transmit her thoughts. She presented a reduced need for sleep, high self-esteem and a great sense of well-being.

As treatment, valproic acid 2000 mg/day, Risperidone 9 mg/day and Clonazepam 3 mg/day were instituted. There was good drug administration and adequate family support. Patient evolved positively with home hospitalization, being later accompanied by in the outpatient service, where maintenance treatment was carried out, evolving with complete remission of the symptoms of mania.

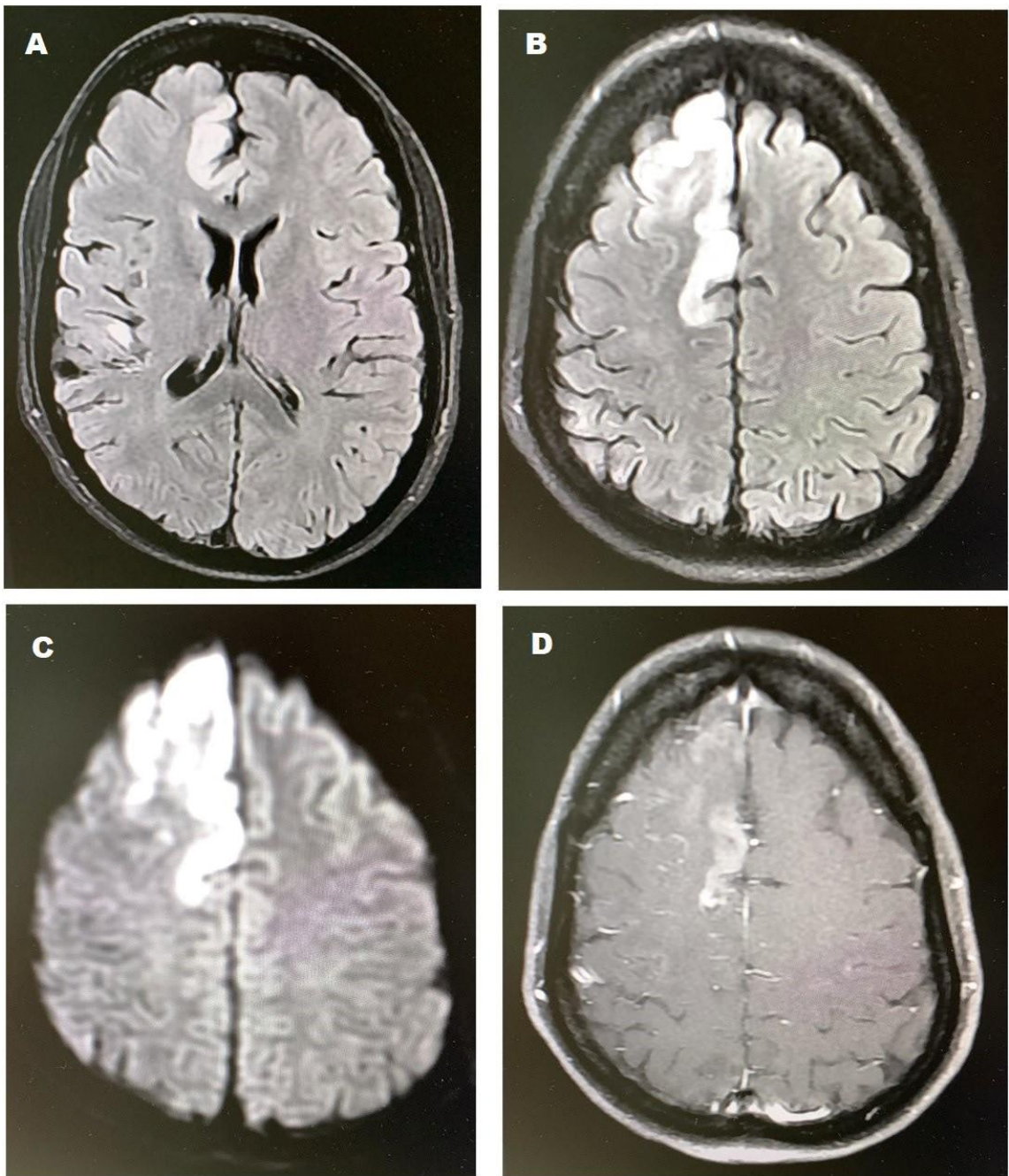


Figure 1: Magnetic resonance imaging of the brain showing hyperintense cortical lesions in FLAIR (A and B) with diffuse restriction (C) and focal enhancement of medium contrast medium (D) in high convexity, in the right superior frontal gyrus, left pre-central gyrus and middle frontal gyrus height on the right.

to cerebral vascular problems. It has also been described as possible explanations for these manifestations in COVID-19 due to transmigration of peripheral immune cells and post-infectious autoimmunity. Furthermore, corticosteroids are frequently used in the treatment of COVID-19, and there is ample evidence of adverse neuropsychiatric effects related to the same, in about 35% of the patients in use. These effects include cognitive and sleep disorders, delirium, hypomania, mania and depression, being typically acute, and disappearing after the end of treatment. In the second case presented, the patient evolved with gradual improvement in the manifold symptoms, simultaneously with the withdrawal of dexamethasone, indicating the possible association of the symptoms with the medication.

In the first reported case, on the other hand, although it is possible that the episode represents the onset of a primary psychiatric illness, the simultaneous diagnosis of COVID-19 and evidence of vasculitis suggest that viral infection is involved in the etiology of the manic symptoms. When the patient's pathological history was evaluated, it was perceived that he had been diagnosed with Anxiety Disorder, with continuous use of Escitalopram 10 mg/day, but with no previous history of depression, mania or hypomania. It is known that the anxiety disorder, when not properly treated, can lead to the development of short, medium and long-term mental disorders. In addition, cases of acute mania and psychosis associated with SARS-CoV-2 infection have been described. In a study conducted in the United Kingdom, altered mental status was described in 31% of the infected patients, and of these, 59% met the clinical definitions for psychiatric disorders, especially recent-onset psychosis.

It is worth noting that hospitalized patients usually experience some degree of psychic suffering, which can manifest in situations such as mood lability, insomnia, anxiety and depression. As there is a need for isolation in the transmission phase of COVID-19, the psychological damage caused by this experience must be considered. The hospitalization of the aforementioned patient lasted more than 15 days, a factor that could have contributed to the emergence of neuropsychiatric alterations.

Even with possible factors co-responsible for the disease process, given the temporal relationship, it is assumed that the viral infection and the drug treatment used may be associated with the neuropsychiatric manifestations described in the clinical cases presented. The long-term prognosis is uncertain and requires further investigation and support.

CONCLUSION

COVID-19 may be associated with the emergence of symptoms of mania, whether due to direct brain injury due to the virus or secondary to the use of medications, such as corticosteroid therapy, as evidenced in both reported cases without work. It is uncertain whether such a deleterious impact will be reversed, or the symptoms will recur in the long term, making it necessary to follow-up longitudinally in two affected patients.

REFERENCES:

1. American Psychiatric Association. **Diagnostic and Statistical Manual of Mental Disorders, Fifth Edition (DSM-5)**. Arlington: American Psychiatric Publishing; 2013.
2. Costa, M., Pavlo, A., Reis, G., Ponte, K., & Davidson, L. **COVID-19 concerns among persons with mental illness**. *Psychiatric Services*, 2020. Nov 1; 71(11):1188-1190.
3. Douaud, G., Lee, S., Alfaro-Almagro, F. *et al.* **SARS-CoV-2 is associated with changes in brain structure in UK Biobank**. *Nature*, 2022. Mar 7. Apr;604(7907):697-707.
4. Duarte TD, Fernandes LF, Freitas MM, Monteiro KC. **Repercussões psicológicas do isolamento de contato: uma revisão**. *Psicologia Hospitalar*, 2015 Aug;13(2):88-113.
5. Hamel L, Lopes L, Muñana C, et al: **KFF Coronavirus Poll: March 2020**. San Francisco, Kaiser Family Foundation, 2020. <https://www.kff.org/global-health-policy/poll-finding/kff-coronavirus-poll-march2020>. Accessed April 9, 2020.
6. Hartung HP, Aktas O. **COVID-19 and management of neuroimmunological disorders**. *Nature Reviews Neurology*, 2020 Jul;16(7):347-8.
7. Lee SH, Shin HS, Park HY, Kim JL, Lee JJ, Lee H, Won SD, Han W. **Depression as a mediator of chronic fatigue and post-traumatic stress symptoms in middle east respiratory syndrome survivors**. *Psychiatry investigation*. 2019 Jan;16(1):59.
8. MacKenzie, M., Daviskiba, S., Dow, M. et al. **The Impact of the Coronavirus Disease 2019 (COVID-19) Pandemic on Healthcare Workers with Pre-Existing Psychiatric Conditions**. *Psychiatr Q*, 2021. Sep;92(3):1011-1020.
9. Margis R, Picon P, Cosner AF, Silveira RD. **Stressful life-events, stress and anxiety**. *Revista de Psiquiatria do Rio Grande do Sul*. 2003 Apr;25:65-74.
10. Mawhinney JA, Wilcock C, Haboubi H, Roshanzamir S. **Neurotropism of SARS-CoV-2: COVID-19 presenting with an acute manic episode**. *BMJ Case Reports CP*. 2020 Jun 1;13(6):e236123.
11. Nalleballe K, Onteddu SR, Sharma R, Dandu V, Brown A, Jasti M, Yadala S, Veerapaneni K, Siddamreddy S, Avula A, Kapoor N. **Spectrum of neuropsychiatric manifestations in COVID-19**. *Brain, behavior, and immunity*. 2020 Aug 1;88:71-4.
12. Okusaga, O., Yolken, R.H., Langenberg, P., Lapidus, M., Arling, T.A., Dickerson, F.B., Scrandis, D.A., Severance, E., Cabassa, J.A., Balis, T. and Postolache, T.T. **Association of seropositivity for influenza and coronaviruses with history of mood disorders and suicide attempts**. *J Affect Disord*, 2011. Apr;130(1-2):220-225.
13. Park SC, Park YC. **Mental health care measures in response to the 2019 novel coronavirus outbreak in Korea**. *Psychiatry investigation*. 2020 Feb;17(2):85.
14. Qiu J, Shen B, Zhao M, et al: **A nationwide survey of psychological distress among Chinese people in the COVID-19 epidemic: implications and policy recommendations**. *Gen Psychiatr* 2020; Mar 6; 33(2):e100213
15. Shejekar S, Nemlekar SS, Srivastava A. **Organic mood disorder: Sequelae of small vessel disease**. *Indian J Psychiatry*. 2019;61(4):420-421.
16. Troyer EA, Kohn JN, Hong S. **Are we facing a crashing wave of neuropsychiatric sequelae of COVID-19? Neuropsychiatric symptoms and potential immunologic mechanisms**. *Brain Behav Immunity*. 2020 Jul;87:34-39.
17. Varatharaj A, Thomas N, Ellul MA, Davies NW, Pollak TA, Tenorio EL, Sultan M, Easton A, Breen G, Zandi M, Coles JP. **Neurological and neuropsychiatric complications of COVID-19 in 153 patients: a UK-wide surveillance study**. *The Lancet Psychiatry*. 2020 Oct 1;7(10):875-82.