

ACHALASIA IN A YOUNG PATIENT: CASE REPORT

Vinicius Magalhães Rodrigues Silva

Doctor, professor at the institution:

Universidade de Ribeirão Preto

<https://orcid.org/0000-0002-6381-076X>

Ada Alexandrina Brom dos Santos Soares

Doctor, resident of Gastroenterology at

the institution: Faculdade de Medicina de

Botucatu-UNESP

<https://orcid.org/0000-0002-7611-7657>

All content in this magazine is licensed under a Creative Commons Attribution License. Attribution-Non-Commercial-Non-Derivatives 4.0 International (CC BY-NC-ND 4.0).



Abstract: Introduction: Achalasia (ACL) is the most common primary motor disorder of the esophagus. Common after the 5th decade of life, it affects both sexes equally. Only 10% are described as idiopathic, where the inhibitory innervation is the most compromised, thus resulting in greater cholinergic activity. The remainder is attributed to chagasic esophagopathy. Dysphagia and regurgitation make up the main symptomatology and, weight loss with consequent malnutrition, the complications. Diagnosis is made by endoscopy, contrast radiology and esophageal manometry (EMN). Thus, in the face of suspicion, it is necessary to review the literature for an accurate diagnosis and effective treatment. Objective: to report a case of ACL in a young patient. Method: review of medical records and literature. Results: D.A.S.S., female, 27 years old, was referred to the gastroenterology clinic with a complaint of dysphagia for 2 years. Associated, there was weight loss, regurgitation and emesis; occasional retrosternal pain and constipation. Having already made use of proton pump inhibitors and prokinetics without success, she was referred for upper digestive endoscopy (EDA) which observed food residues in the esophagus. Afterwards, an esophagogram (EFG) was performed, which defined megaesophagus. Subsequently submitted to MNE, she was diagnosed with lower esophageal sphincter (LES) with normal basal pressure, without complete relaxation, in addition to esophageal body with simultaneous waves. She was referred to the digestive surgery outpatient clinic. Discussion: ACL is not frequent in young people. Diagnosis is delayed by up to 5 years. The first exam must be the EDA. The EFG demonstrates "bird's beak", and the MNE, aperistaltic or simultaneous waves in addition to absent or incomplete relaxation of the LES. The definitive treatment is surgical.

Conclusion: When in elderly people with Chagas' esophagopathy, the diagnosis of ACL is common. However, when it affects young people, there is a need for a study to exclude confounding factors, perform the correct choice and interpretation of exams, so that the diagnosis and treatment are effective.

Keywords: Achalasia; Manometry; dysmotility.

INTRODUCTION

Esophageal achalasia, first described by Thomas Willis in 1674, is an esophageal motility disorder characterized by partial or absent relaxation of the lower esophageal sphincter (LES) and/or aperistalsis of the esophageal body.^{5,13} Despite representing the most well-known and common esophageal motor disorder, it is a rare disease with a prevalence of 0.01% of the population and equal distribution in terms of gender and race, but with an incidence that increases with age.^{12,15}

Achalasia is predominantly an idiopathic disease due to autoimmune phenomena in response to unknown antigens.¹² However, it can also occur secondary to Chagas disease by the action of *Trypanosoma cruzi*, found mainly in Central and South America.¹

The pathophysiology involves the loss of cells from the myenteric plexuses of Auerbach (inhibitory neurons) and Meissner's plexuses (excitatory neurons), the latter being injured to varying degrees, corroborating variations in the clinical presentation of the disease.² In idiopathic achalasia, there is a prevalence of injury to the inhibitory innervation, whereas in Chagas disease, the lesions compromise both the inhibitory and excitatory innervation.^{5,12}

The most common clinical manifestations are dysphagia, which may present at the beginning for both solid and liquid (70-97%), regurgitation of undigested food (75%) and

weight loss (60%), due to lower ingestion and esophageal emptying, ineffective. Other symptoms may be present, such as chest pain, respiratory complications (aspiration pneumonia), and heartburn^{2,13,15}. Therefore, the main differential diagnoses in the face of a suspicion of esophageal achalasia include Gastroesophageal Reflux Disease (GERD), pseudoachalasia derived from tumors of the cardia, pancreas, breast, lung or liver, and achalasia secondary to previous surgeries.¹⁵

After clinical suspicion, among the main complementary tests for the diagnosis of esophageal achalasia, esophageal manometry is considered the gold standard, demonstrating incomplete or absent LES relaxation, LES hypertonia and loss of esophageal peristalsis. Another essential test to be performed is barium esophagography, which allows the visualization of contrast retention and application of the Resende scale, assessing the degree of dilatation in the study of contrasted esophagus, incoordination of transit and narrowing of the esophagogastric transition. In addition to these tests, Upper Digestive Endoscopy (EDA) is extremely important, since it can show retention of food, liquids and saliva in the esophagus, without other apparent causes that explain this fact, such as tumors, allowing the exclusion of pseudoachalasia.^{2,13,15}

Although the treatment does not act on the etiological factor, it is essential for the relief of symptoms, being based on reducing or even “stopping” the tonus of the LES.¹³ Among the therapeutic measures, dietary, pharmacological, endoscopic and surgical approaches are included.² However, the advantages of each treatment option must be individualized for each patient.¹³

GOAL

To report a case of achalasia in a young patient, uncommon involvement in this age

group, requiring a persevering study of the case in order to exclude confounding factors to obtain an accurate diagnosis and effective treatment.

METHODOLOGY

For the preparation of this article, the information presented was obtained through the analysis of medical records and literature review in cataloged information bases. The work was submitted to the Research Ethics Committee, with the identification number, CAAE: 02069018.8.0000.5498.

CASE REPORT

D.A.S.S., female, 27 years old, was referred to the gastroenterology outpatient clinic due to the onset of progressive dysphagia 2 years ago. Associated with this complaint, he presented weight loss of 9 kg in the period, episodes of regurgitation, bloating and postprandial emesis, and occasionally retrosternal pain and constipation. She started using proton pump inhibitors and prokinetics, but there was no symptomatic improvement, being referred for UDE, which questioned the presence of food residues in the esophagus. After this result, a Barium Esophagography exam was requested (Figure 1), showing grade II megaesophagus, and therefore submitted to Esophageal Manometry, which showed LES with normal basal pressure and without complete relaxation, in addition to the presence of simultaneous waves of the esophageal body (Figure 2). In this context, a diagnosis of achalasia was performed and the patient was referred for treatment by peroral endoscopic myotomy (POEM).

DISCUSSION

The most frequent symptoms of achalasia are: dysphagia (>90%), regurgitation (76-91%), nocturnal cough (30%), aspiration

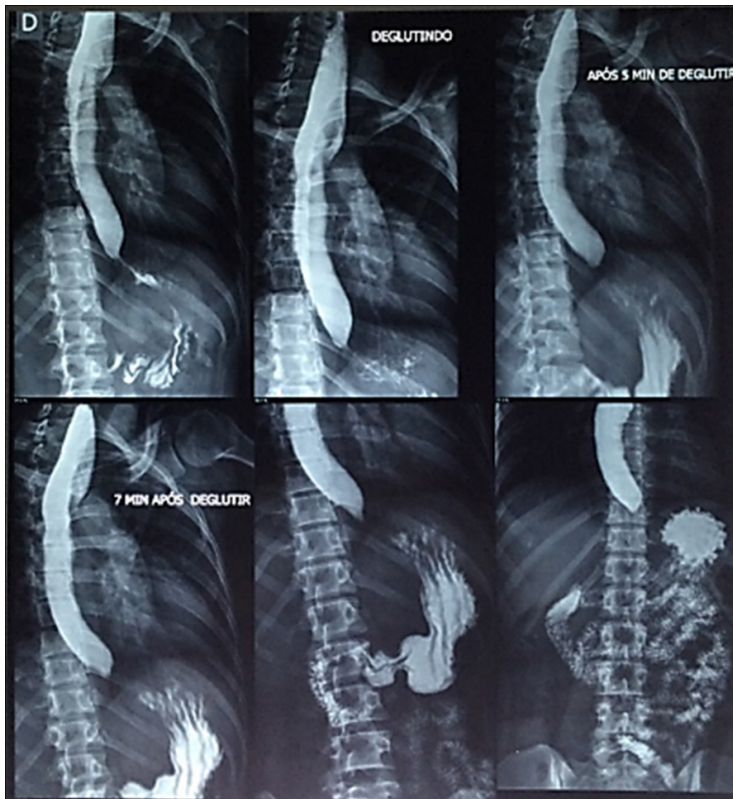


Figure 1. Barium Esophagography image demonstrating “bird’s beak” tapering in the distal segment of the esophagus.

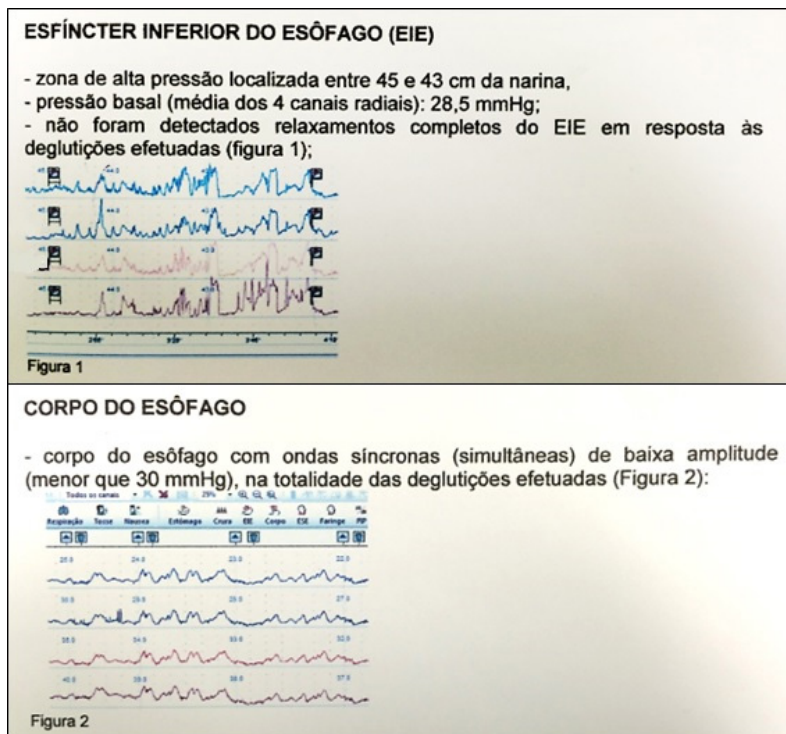


Figure 2. Esophageal Manometry image demonstrating incomplete LES relaxation (Fig. 1) and simultaneous waves in the esophageal body (fig. 2).

pneumonia (8%), chest pain (25-64%), heartburn (18%). -52%) and weight loss (35-91%). Heartburn can confuse the diagnosis with gastroesophageal reflux disease. In some cases, culminate in inadvertent fundoplication surgery. Symptoms of achalasia are not specific. This explains the long delay between the onset of symptoms and the final diagnosis. Some studies have shown up to 5 years apart. Although some patients lose a lot of weight (more than 20 kg), achalasia must also be considered in obese patients.³

The first diagnostic step is to rule out anatomic lesions, neoplasia, or pseudoachalasia using endoscopy or radiology.⁷ Especially in the early stage, both endoscopy and radiology are less sensitive than manometry and identify only about 50% of patients with early stage achalasia. Radiological examination usually shows a typical image of a bird's beak at the junction, with a dilated esophageal body, sometimes with an air-fluid level and absence of an intragastric air bubble.^{8,9} In conventional manometry, there is absence of peristalsis and incomplete relaxation of the LES during swallowing, which has residual pressure > 10 mmHg. In addition, the resting tone of the LES is increased¹⁶. High-resolution manometry (HRM) is increasingly being used to provide more detailed information on esophageal motility. It is currently considered the gold standard for the diagnosis of esophageal dysmotility. The use of this tool allowed the subclassification of achalasia into three clinically relevant groups based on the contractility pattern in the esophageal body: type I: classical achalasia, without evidence of pressurization, type II: achalasia with compression or compartmentation in the distal esophagus > 30 mmHg, and type III: two or more spastic contractions of the esophagus⁴.

Treatment is designed by pharmacology, endoscopic and surgical interventions. The two most commonly used drugs are nitrates and calcium channel blockers. Nitrates inhibit the normal contraction of the LES by dephosphorylating the myosin light chain. Nifedipine, for example, inhibits muscle contraction by blocking cellular calcium uptake and thus reduces resting EIE pressure by 30-60%. However, a substantial disadvantage of its use is the occurrence of side effects such as hypotension, headache and dizziness that occur in up to 30% of patients.¹⁰ Another proposed pharmacological treatment is botulinum toxin A, a neurotoxin that blocks the release of acetylcholine from nerve endings. The drug is injected directly into the EIE through the EDA. The toxin is safe, effective, and has few side effects. More than 80% of cases have a clinical response within 30 days, but there is early recurrence, with less than 2/3 of patients maintaining remission at 1 year after application.¹⁴ Pneumatic balloon dilation promotes shearing of the LES muscle fibers by forced stretching. Dilations are subsequent and spaced at 2- to 4-week intervals based on symptom relief associated with repeated LES pressure measurements or improvement in esophageal emptying.¹⁸ Surgical myotomy of the muscular layer of the distal esophagus and LES, also known as Heller's myotomy, is an established treatment for achalasia. It was first described in 1913 by Ernst Heller, and has been in wide use, with little technical change, since then. The two most important modifications of the original procedure are the splitting of the cardia muscle fibers only on the anterior aspect and the addition of a fundoplication to reduce the risk of gastroesophageal reflux.⁶ Peroral endoscopic myotomy (POEM) is a recently developed endoscopic technique. In summary, the endoscopist creates a submucosal tunnel

to reach the LES and dissect the circular muscle fibers along 7 cm in length in the distal esophageal portion and 2 cm in length in the proximal gastric portion.¹¹. Despite the effectiveness of pneumodilation, Heller's laparoscopic myotomy, and other forms of treatment described, 2-5% of patients will develop end-stage disease, which is defined as massive dilation of the esophagus with food retention, reflux disease not responsive or presence of pre-neoplastic lesions. In these cases, esophageal resection may be necessary to improve the patient's quality of life and avoid the risk of invasive esophageal carcinoma.¹⁷.

CONCLUSION

When in elderly people with Chagas' esophagopathy, the diagnosis of achalasia is common. However, when it affects young people and in the early stages of the disease, there is a need for a dedicated case study to exclude confounding factors. The choice and decision to perform, as well as the correct interpretation of the exams, is essential for confirmation and classification of the condition. In addition, the appropriate therapeutic modality must be defined so that there is improvement in symptoms, quality of life and prevention of complications.

REFERENCES

1. Ahmed A. **Achalasia: What is the best treatment?** Ann Afr Med 7.3 (2008), pp. 141-148
2. Andrade DS, et al. **Abordagem terapêutica da Acalásia de Esôfago: relato de caso.** REAS/EJCH 13.1 (2021), e5333
3. Boeckstaens GE, Zaninotto G, Richter JE. **Achalasia.** The Lancet. January 2014
4. Bredenoord AJ, Fox M, Kahrilas PJ, et al. **Chicago classification criteria of esophageal motility disorders defined in high resolution esophageal pressure topography.** Neurogastroenterol Motil, 24 (suppl 1) (2012), pp. 57-65
5. Dantas RO. **Comparison between idiopathic achalasia and achalasia caused by Chagas' disease: a review about the pathophysiology of the diseases.** Arq Gastroenterol 40.2 (2003), pp. 126-130
6. Dor J, Humbert P, Paoli JM, et al. **Treatment of reflux by the so-called modified Heller-Nissen technic.** Presse Med, 75 (1967), pp. 2563-2565
7. Eckardt VF. **Clinical presentations and complications of achalasia.** Gastrointest Endosc Clin N Am, 11 (2001), pp. 281-292 vi
8. El-Takli I, O'Brien P, Paterson WG. **Clinical diagnosis of achalasia: how reliable is the barium x-ray?** Can J Gastroenterol, 20 (2006), pp. 335-337
9. Fisichella PM, Raz D, Palazzo F, et al. **Clinical, radiological, and manometric profile in 145 patients with untreated achalasia.** World J Surg, 32 (2008), pp. 1974-1979
10. Gelfond M, Rozen P, Gilat T. **Isosorbide dinitrate and nifedipine treatment of achalasia: a clinical, manometric and radionuclide evaluation.** Gastroenterology, 83 (1982), pp. 963-969
11. Inoue H, Minami H, Kobayashi Y, et al. **Peroral endoscopic myotomy (POEM) for esophageal achalasia.** Endoscopy, 42 (2010), pp. 265-271
12. Laurino-Neto RM, et al. **Evaluation of esophageal achalasia: from symptoms to the Chicago classification.** ABCD. Arq Bras Cir Dig 31.2 (2018), e1376
13. Leonardi CJ, Cury M. **Estudo prospectivo para tratamento de achalasia pela técnica de miotomia endoscópica POEM (Peroral Endoscopy Myotomy).** GED gastroenterol endosc dig 33.1 (2014), pp. 7-13

14. Leyden JE, Moss AC, MacMathuna P. **Endoscopic pneumatic dilation versus botulinum toxin injection in the management of primary achalasia.** Cochrane Database Syst Rev, 4 (2006). CD005046
15. Lopes GA, et al. **Acalasia de esôfago idiopática: Relato de caso e revisão da literatura.** Braz J Hea Rev 3.5 (2020), pp. 12267-12275
16. Richter JE, Boeckxstaens GE. **Management of achalasia: surgery or pneumatic dilation.** Gut, 60 (2011), pp. 869-876
17. Triadafilopoulos G, Boeckxstaens GE, Gullo R, et al. **The Kagoshima consensus on esophageal achalasia.** Dis Esophagus, 25 (2012), pp. 337-348
18. Vela MF, Richter JE, Khandwala F, et al. **The long-term efficacy of pneumatic dilatation and Heller myotomy for the treatment of achalasia.** Clin Gastroenterol Hepatol, 4 (2006), pp. 580-587