

## MANUAL FOR INTERPERTATION OF THE SIMPLIFIED BIOPHYSICAL PROFILE IN THE ASSESSMENT OF ACUTE FETAL DISTRESS

---

**Ana Mozer Vieira de Jesus**

Universidade Tiradentes, Aracaju

<http://lattes.cnpq.br/2822030363557017>

**Ramilly Guimarães Andrade Santos**

Universidade Tiradentes, Aracaju

<http://lattes.cnpq.br/5509896112600945>

**Natália Araújo Barreto**

Universidade Tiradentes, Aracaju

<http://lattes.cnpq.br/0553473986481540>

**Ana Cecília de Menêzes Nóbrega**

Universidade Tiradentes, Aracaju

<http://lattes.cnpq.br/2761924310770096>

**Ketlen Natany Goes Xavier**

Universidade Tiradentes, Aracaju

<http://lattes.cnpq.br/2562884109024124>

**Beatriz Mariana de Andrade Guimarães**

Universidade Tiradentes, Aracaju

<http://lattes.cnpq.br/2161509179508637>

**Luiz Felipe Santos Dias**

Universidade Tiradentes, Aracaju

<http://lattes.cnpq.br/8845408940960261>

**Isabela Avila Fontes Carvalho**

Universidade Tiradentes, Aracaju

<http://lattes.cnpq.br/228938883236132>

All content in this magazine is licensed under a Creative Commons Attribution License. Attribution-Non-Commercial-Non-Derivatives 4.0 International (CC BY-NC-ND 4.0).



***Julio Cezar de Oliveira Filho***

Universidade Federal de Sergipe, Aracaju  
<http://lattes.cnpq.br/6063722098813881>

***Gustavo Alves Aguiar***

Universidade Tiradentes, Aracaju  
<http://lattes.cnpq.br/9996675569219609>

***Fernanda Priscilla Barbosa Silva***

Universidade Tiradentes, Aracaju  
<http://lattes.cnpq.br/2002582003348621>

***Maria Eduarda Tavares Brito***

Universidade Tiradentes, Aracaju  
<http://lattes.cnpq.br/3828241104116436>

**Abstract: Introduction:** Acute fetal distress (AFS) is an important cause of neonatal morbidity and mortality, making up the list of obstetric emergencies. The realization of the simplified biophysical profile is a reality in health services, especially public ones, due to the observation that cardiotocography (CTG) is the primary and most sensitive alteration for the perception of AFS, and can be complemented only with the assessment of amniotic fluid - important to reflect chronicity of suffering - without significantly modifying the quality of clinical diagnosis or risk stratification. The present study, therefore, aims to provide a simplified biophysical profile interpretation manual in the assessment of acute fetal distress in order to facilitate the clinical management of these patients.

**Methodology:** This is a literature review in the Scielo, PubMed, Lilacs and Google Scholar databases, in addition to treatises on Gynecology and Obstetrics by Febrasgo and Zugaib. Nine articles were selected from 1999 to 2022, regardless of the country of origin, correlated with different aspects of the theme, as there is still little published material with these descriptors. The time frame was not predetermined, being only a reflection of the oldest to the most recent materials that fit the theme. However, articles whose discussion did not corroborate the interpretation of the simplified biophysical profile were excluded.

**Results:** Cardiotocography assesses fetal heartbeat, uterine contraction (through maternal perception under a handheld device), and fetal movement. To interpret its findings, one must consider: baseline fetal heart rate, variability, accelerations and decelerations. The detection of amniotic fluid alterations at any stage of pregnancy must be investigated from both a fetal and maternal point of view. It can be assessed semi-quantitatively by measuring the largest pocket or amniotic fluid index or by subjective

assessment. **Conclusions:** Since fetal distress strongly implies the outcome of pregnancy, early detection through the simplified biophysical profile is essential for adequate and timely therapeutic indication. To facilitate the interpretation of cardiotocographic and amniotic fluid findings, a sequence that facilitates this process can be used. In view of the result of the simplified antepartum BFP, the severity and stability of the maternal clinical picture and the gestational age must always be taken into account to establish the obstetric management.

**Keywords:** Simplified biophysical profile, High risk pregnancy, Cardiotocography, amniotic fluid. fetal distress.

## INTRODUCTION

Acute fetal distress (AFS) is an important cause of neonatal morbidity and mortality, making up the list of obstetric emergencies. During intrauterine life, the placenta, through the intervillous space, functions as an area for maternal-fetal gas exchange. The umbilical vein carries oxygenated blood from the placenta towards the fetus, while the umbilical arteries return deoxygenated blood from the fetus to the placenta.

The fetus is subject to several intrinsic risk factors, as well as antepartum and peripartum events that may condition a complete or partial

cessation of placental gas exchange, being the main mechanism contributing to the sudden and temporary decrease in uteroplacental circulation. These events can result in hypoxemia and consequent respiratory acidemia, which, under normal conditions, can be quickly corrected after gas exchange is established. However, the prolongation of these changes can lead to AFS, which is defined as a state of persistent hypoxia and metabolic acidosis, with subsequent perinatal asphyxia and irreversible damage to newborns.

FAS presents with a sudden loss of oxygen, usually during labor, and requires immediate intervention. Chronic fetal distress (CFS) is a progressive loss of oxygen that can be identified during prenatal care through intrauterine growth restriction, alteration in Doppler flowmetry, presence of oligohydramnios, among others.

The technical progress developed by real-time ultrasound methods allowed the accurate and safe observation of many fetal motor activities, unexplained until a decade ago. Taking this preamble into account, it can be concluded that the tests used to determine antepartum fetal well-being, among others the biophysical profile (PBF), have a general consensus for use in pregnant women with some potential or real risk. Table 1 brings together the components of the BFP.

Complete biophysical profile	Simplified biophysical profile
Cardiotocography associated with 4 ultrasound parameters, including: <ul style="list-style-type: none"> <li>• Amniotic fluid,</li> <li>• Fetal movement,</li> <li>• Fetal respiratory movement,</li> <li>• Fetal tone.</li> </ul>	Cardiotocography + assessment of amniotic fluid.

Table 1. Components of the complete and simplified fetal biophysical profile.

The implementation of the simplified PBF is a reality in health services, especially public ones, due to the observation that cardiotocography (CTG) is the primary and most sensitive alteration for the perception of AFS, and can be complemented only with the assessment of amniotic fluid - important for reflect chronicity of suffering – without significantly modifying the quality of clinical diagnosis or risk stratification.

The present study, therefore, aims to provide a simplified biophysical profile interpretation manual in the assessment of acute fetal distress in order to facilitate the clinical management of these patients.

## METHODOLOGY

This is a literature review, whose search terms were “Simplified biophysical profile”, “High-risk pregnancy”, “Cardiotocography”, “Amniotic fluid” and “Fetal distress” in the Scielo, PubMed, Lilacs and Google Scholar, in addition to treatises on Gynecology and Obstetrics by Febrasgo and Zugaib. Nine articles were selected from 1999 to 2022, regardless of the country of origin, correlated with different aspects of the theme, as there is still little published material with these descriptors. The time frame was not predetermined, being only a reflection of the oldest to the most recent materials that fit the theme. However, articles whose discussion did not corroborate the interpretation of the simplified biophysical profile were excluded.

## RESULTS

### CARDIOTOCOGRAPHY

It is an exam performed for 20 to 30 minutes, on average, through the placement of two electrodes on the mother’s skin, at a time outside of prolonged maternal fasting. It assesses fetal heartbeat, uterine contraction (through maternal perception under a

handheld device), and fetal movement. To interpret your findings, one must consider:

#### 1. Baseline fetal heart rate - baseline

The normal fetal heart rate ranges from 110 to 160 beats per minute. The baseline must match this spectrum. To be recognized, an average fetal heart rate must be obtained within 10 minutes.

Therefore, the fetus will be in tachycardia if the frequency is higher than 160 bpm - in general, caused by maternal variables such as hyperthermia, anxiety, thyrotoxicosis and drug use, by intrauterine infection, by fetal hypoxia, by fetal heart disease, by constitutional factors - or bradycardia if less than 110 bpm – usually due to fetal hypoxia, fetal heart disease, the action of drugs used by the mother, constitutional factors.

#### 2. Variability

It represents the difference between the largest and smallest fetal heartbeat and demonstrates the integrity of the autonomic nervous system.

The variability will be satisfactory (increased) if the result of this difference is greater than 25 bpm or reassuring (moderate) if between 6 and 25. However, it will be alert (minimal) if less than or equal to 5 (Figure 1) and terminal pattern (absent) if 0.

There is the sinusoidal pattern (figure 2), in which there is a wave pattern that mimics sine waves with a variability of 3-5 beats per minute that persists for 20 minutes or more. This pattern can be seen in the severely anemic fetus (hemoglobin dosage less than 7g%).

#### 3. Accelerations

They are characterized by an increase of 15 bpm sustained for at least 15 seconds (Figure 2) and represent motor activity of the conceptus or reaction to uterine contractions. In fetuses with a gestational age of less than 32

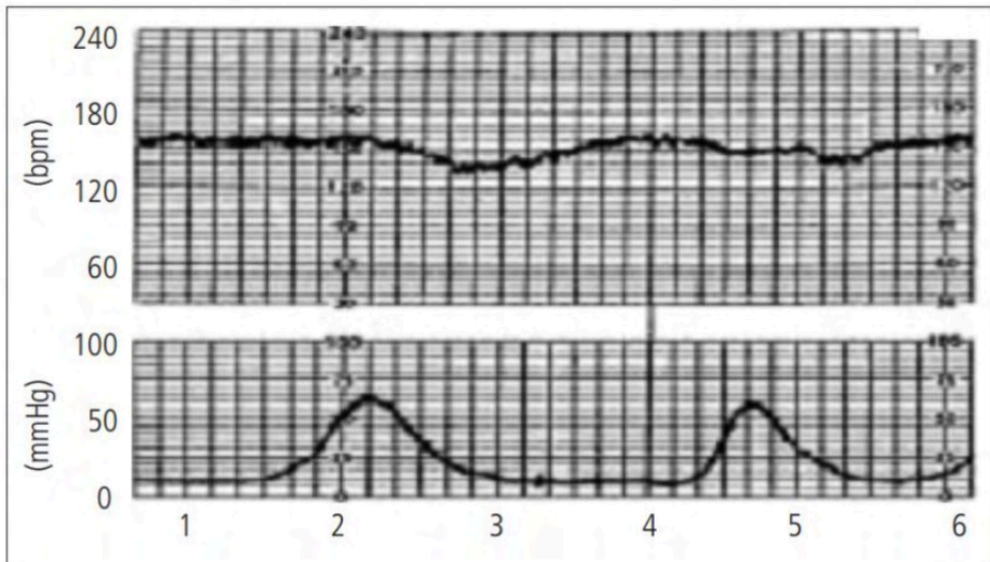


Figure 1. Cardiocotography – minimal variability.

Source: MELO et al., Instituto de Medicina Integral Professor Fernando Figueira (IMIP) – Recife (PE), Brazil. 2011.

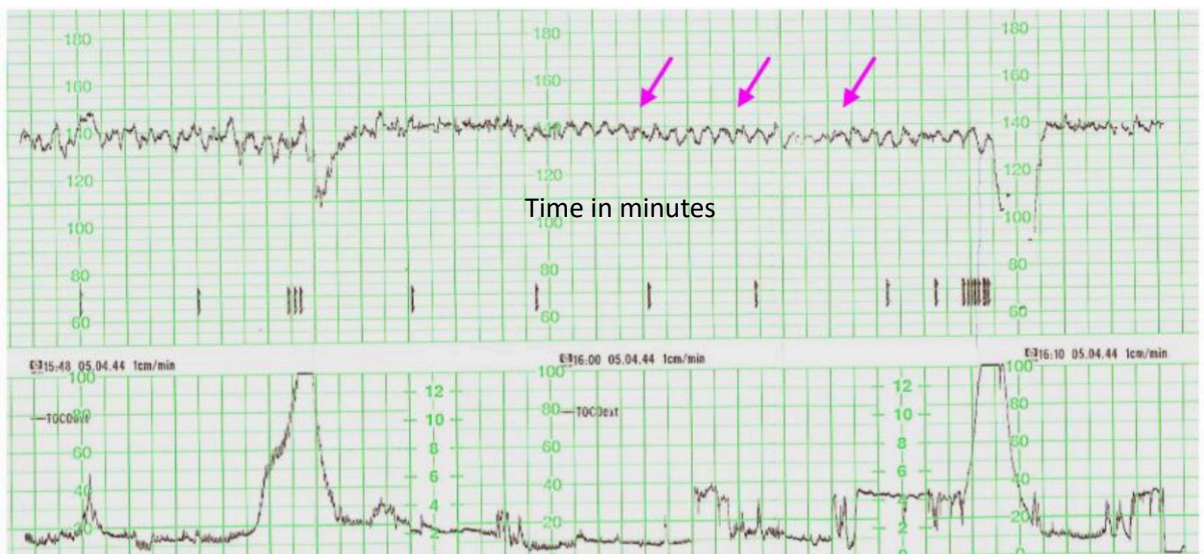


Figure 2. Sinusoidal tracing (arrows). Note the absence of reactivity criteria in the recording and the presence of late-onset decelerations.

Source: Barata et al., Department of Obstetrics, Gynecology and Reproductive Medicine, Hospital Santa Maria, Lisbon. 2009

weeks, the presence of 10 bpm for 10 seconds can be considered acceleration.

It will be reassuring if at least 2 accelerations are present in a 20-minute period (Figure 3). However, it is important to recognize that the physiological period of fetal sleep or the action of a sedative drug administered to the mother interferes with active fetal movement and, therefore, does not accelerate the heart rate, even when healthy.

Absence of accelerations indicates acidosis in approximately 50% of cases, in addition to being the first occurrence observed on CTG regarding fetal hypoxia.

#### 4. Decelerations

Transient drop in fetal heart rate that returns to baseline. They may or may not have clinical repercussions. When the uterine contraction indicated by the mother on the tocogram during labor is present, the decelerations can be called intrapartum decelerations (IPD) classified as early or late.

**DIP 1 (or early or cephalic):** deceleration coincides with metrosystole and indicates cephalic compression, not fetal distress (Figure 4). It is more common in front of the broken bag. In general, they are considered to be benign.

**DIP 2 (or late):** deceleration occurs after contraction (Figure 5). It is a pattern more associated with acute fetal distress and may indicate intrauterine resuscitation and faster delivery.

**DIP 3 (or variables):** there is no pattern related to contraction. It may occur due to possible funicular compression and is usually not pathological, requiring only observation in favorable cases, as there is a rapid return to baseline with secondary acceleration of fetal heart rate. Complicated variable decelerations are decelerations in which fetal heart rate reaches values below 70 beats per minute lasting longer than 60 seconds, loss of fetal

heart rate variability during deceleration, biphasic deceleration, secondary prolonged acceleration (increment of more than 20 beats per minute and/or duration of more than 20 seconds post-deceleration), slow return to baseline at a level lower than that present before deceleration or at the level of fetal tachycardia or bradycardia.

#### 5. Cardiotocography classification

After this assessment, the CTG can be classified as Category 1, 2 or 3. It will be Category 1 (Figure 6) if BCF 110-160 bpm, normal variability, no DIP 2 or 3, acceleration present/absent. It will be category 3 if without variability (< 5), with recurrent PID 2 or 3, or bradycardia – and obstetric intervention must be performed. Category 2 is variable and must be consulted on a case-by-case basis when the exam result does not compose either category 1 or category 3.

#### AMNIOTIC FLUID ASSESSMENT (LA)

The main functions of LA are dissipation of uterine forces applied to the fetus, minimization of energy expenditure for fetal movements essential to its development, thermoregulation, support for fetal and uterine growth, bacteriostatic properties, prevention of umbilical cord compression, deposit of fetal excreta and improved ultrasound acuity.

The detection of LA alterations at any stage of pregnancy must be investigated from both a fetal and maternal point of view. It can be assessed semi-quantitatively by measuring the largest pocket or amniotic fluid index or by subjective assessment. The parameters are expressed in table 2.

It is worth mentioning that reductions in AT represent the main chronic marker of reduced nutritional supply to the fetus.

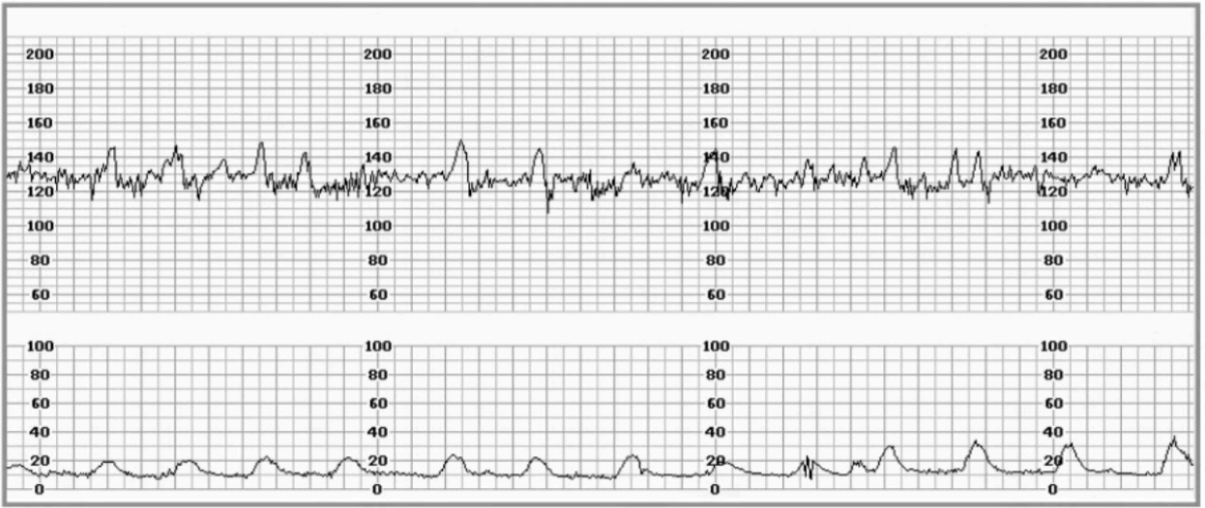


Figure 3. CTG demonstrating fetal heart rate accelerations.  
 Source: TODD et al., Brazilian Society of Anesthesiology. 2013.

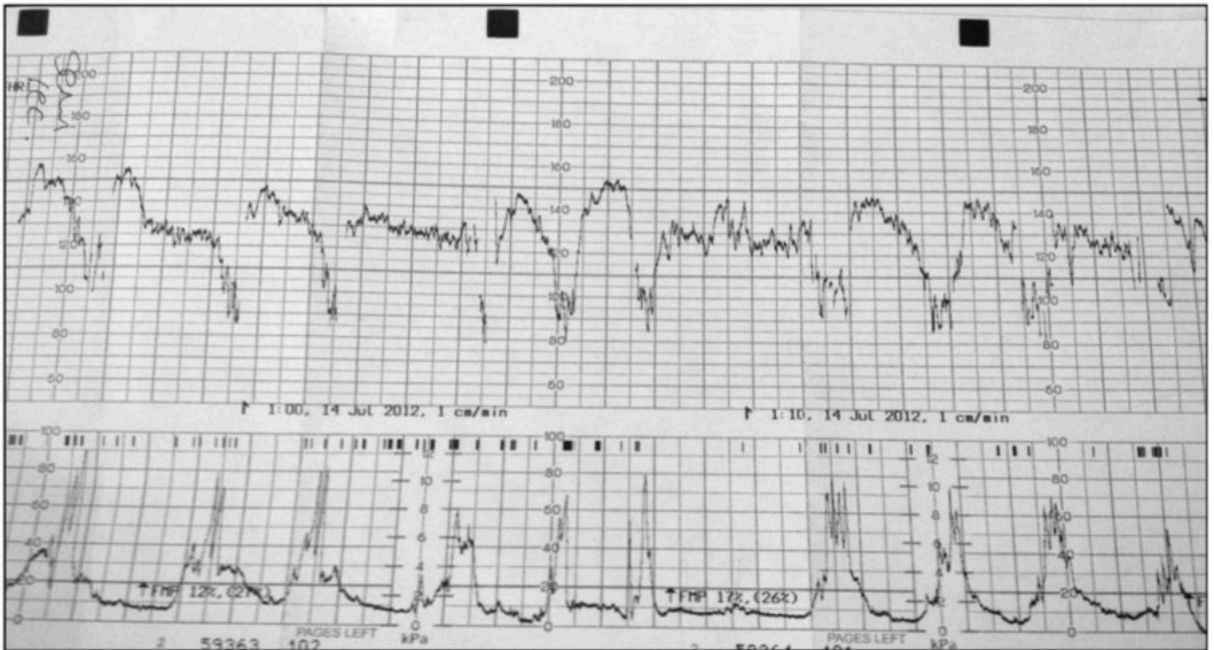


Figure 4. CTG demonstrating early decelerations. Note: the onset of deceleration occurs with the onset of uterine contraction.  
 Source: TODD et al., Brazilian Society of Anesthesiology. 2013

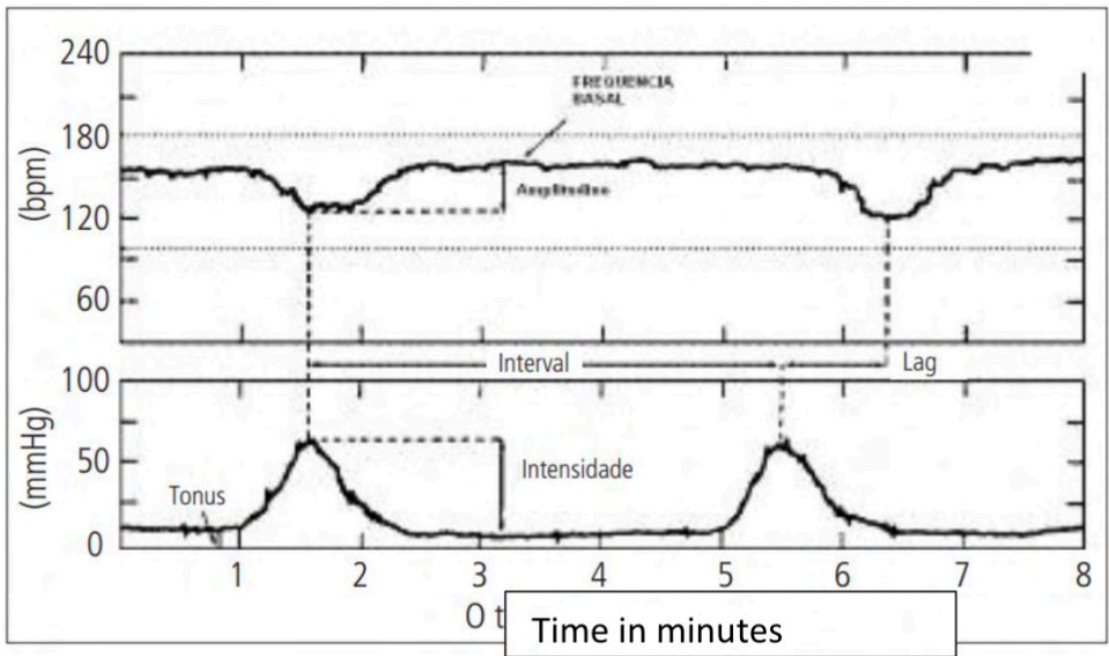


Figure 5. Cardiotocography – delayed deceleration.

Source: MELO et al., Instituto de Medicina Integral Professor Fernando Figueira (IMIP) – Recife (PE), Brazil. 2011.

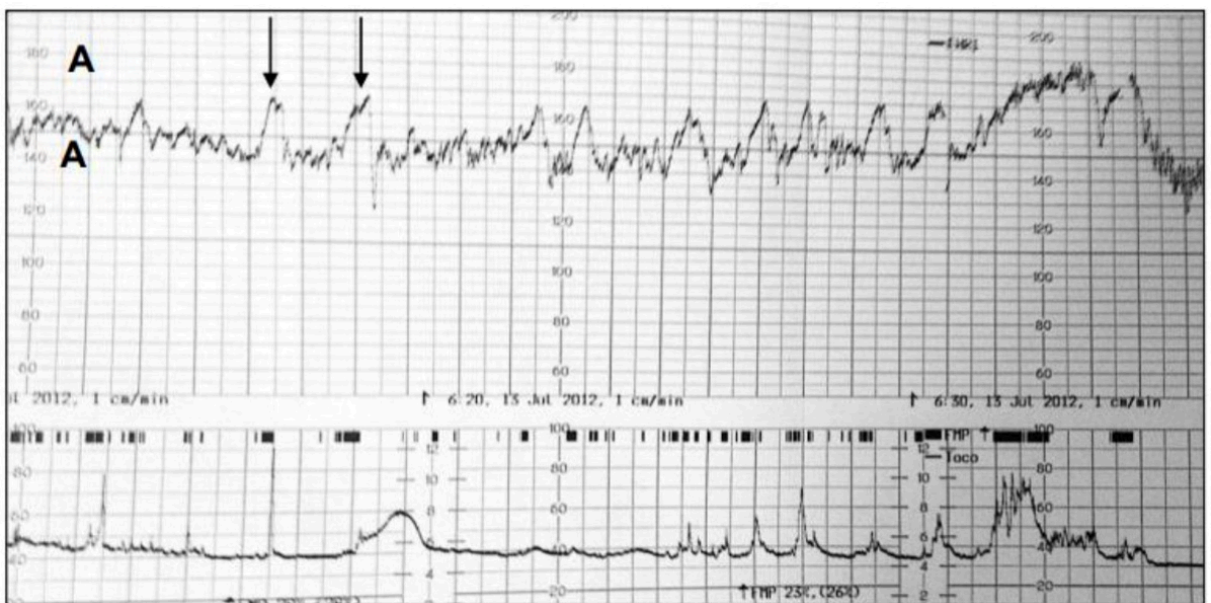


Figure 6. Normal CTG, above (A), and tocogram showing uterine contractions, below (B). Fetal heart rate is within the normal range and has normal baseline variability. Arrows demonstrate healthy fetal heart rate accelerations. Reassuring pattern.

Source: Todd et al., Brazilian Society of Anesthesiology.



A bigger pocket	Amniotic fluid index	Interpretation
< 2 cm	< 5 cm	Oligohydramnios
Between 2-3 cm	Between 5-8 cm	Reduced
Between 4-8 cm	Between 8-18 cm	Normal

Table 2. Assessment of amniotic fluid volume by ultrasound.

CARDIOTOCOGRAPHY	
Topic	Reference
Baseline	110-160 bpm
Variability	6 at 25 bpm ≤ 5 bpm for < 40 min
Accelerations (> 32 weeks)	≤ 2 acelerações ≥ 15 bpm por 15 seconds
Accelerations (< 32 weeks)	≥ 2 acelerações ≥ 10 bpm por 10 seconds
Decelerations	None or occasional/variable, < 30 seconds
AMNIOTIC FLUID	
Topic	Reference
A bigger pocket	In between 4-8 cm
Index of LA	In between 8-18 cm

Table 3. Simplified biophysical profile interpretation in the assessment of acute fetal distress.

## CONCLUSIONS

In some women, a spectrum of diverse clinical conditions defines high gestational risk. Cases such as meconium staining in amniotic fluid, maternal fever, use of oxytocin to accelerate labor, bleeding in labor, abnormal fetal heart rate detected during intermittent auscultation, clinical diseases adjacent to pregnancy, among others, may require continuous maternal-fetal surveillance.

Since fetal distress strongly implies the outcome of pregnancy, early detection through the simplified biophysical profile is essential for adequate and timely therapeutic indication. To facilitate the interpretation of cardiotocographic and amniotic fluid findings, a sequence that facilitates this process can be used (Table 3).

In view of the result of the simplified antepartum PBF, the severity and stability of the maternal clinical picture and the gestational age must always be taken into account to establish the obstetric approach.

## REFERENCES

BARATA, Sónia et al. Caso Clínico/Case Report. **Acta Obstet Ginecol Port**, v. 3, n. 3, p. 169-172, 2009.

BERRONES, Miguel Ángel Serrano; CASTILLO, Indra Beltrán; BERRONES, José Román Serrano. Perfil biofísico para conocer el bienestar fetal. **Revista de Especialidades Médico-Quirúrgicas**, v. 17, n. 4, p. 300-307, 2012.

DE CUIDADO, Guia do Episódio. Distúrbios do Líquido Amniótico.

FERREIRO, Ricardo Manuel. Perfil biofísico: una prueba de bienestar fetal. **Revista Cubana de Obstetricia y Ginecología**, v. 25, n. 2, p. 77-82, 1999.

KOBAYASHI, Sergio. Avaliação ultra-sonográfica do volume do líquido amniótico. **Radiologia Brasileira**, v. 38, n. 6, p. V-VI, 2005.

MASCARO, Moacyr Sanches et al. Cardiotocografia anteparto e prognóstico perinatal em gestações complicadas pelo diabetes: influência do controle metabólico materno. **Revista Brasileira de Ginecologia e Obstetrícia**, v. 24, p. 593-599, 2002.

MELO, Adriana Suely de Oliveira; SOUZA, Alex Sandro Rolland; AMORIM, Melania Maria Ramos. Avaliação biofísica complementar da vitalidade fetal. **Femina**, p. 303-312, 2011.

MARTINS, Mariana Salomé Pereira. **Sofrimento Fetal Agudo**. 2020. Tese de Doutorado.

SILVEIRA, Sheila Koettker; JÚNIOR, Alberto Trapani. MÉTODOS DE AVALIAÇÃO DA VITALIDADE FETAL INTRAPARTO. **FEMINA**, v. 48, n. 1, p. 59-64, 2020.