

**CORRELATION
BETWEEN ELBOW
PERIMETRY AND
GARTHLAND
CLASSIFICATION IN
CHILDREN WITH ACUTE
DIAGNOSIS OF SUPRA
CONDYLIAN ELBOW
FRACTURE**

Bruno Finoti Barini

<http://lattes.cnpq.br/3753604424139511>

Daniel Pereira Barbosa

<http://lattes.cnpq.br/7852566098126335>

Luis Eduardo de Lábio Parra

<http://lattes.cnpq.br/1053461032281284>

Marina Parzewski Moreti

<http://lattes.cnpq.br/5314315480722867>

All content in this magazine is licensed under a Creative Commons Attribution License. Attribution-Non-Commercial-Non-Derivatives 4.0 International (CC BY-NC-ND 4.0).



Abstract: Introduction: The supracondylar fracture of the humerus is typical of the immature skeleton, representing a high rate of care provided in orthopedic emergency units. The most used classification is described by Garthland, and it has 3 different types, according to the deviation of the coronal plane in the elbow radiographs, each one with its appropriate therapeutic indication. Objective: To assess the correlation between the perimetry of the fractured elbow and its contralateral elbow, classifying it according to Garthland. Methodology: Study carried out with children up to 12 years old with a diagnosis of supracondylar fracture treated in the emergency department of a tertiary hospital in the city of Franca - SP. The following data were collected: age, gender, side affected, time of trauma, Garthland classification, perimetry of both upper limbs. Results and discussion: Thirty-three children were evaluated, with a mean age between 5-6 years and a higher prevalence of fractures in the left upper limb. The average time between injury and medical care was a maximum of 6 hours. Garthland's type I classification represented 49% of fractures, but the greatest difference, 5.01 cm, in perimetry was found in type III. Conclusion: There is a greater difference in perimetry in fractures of higher severity. This data can help the orthopedist and pediatrician in the initial evaluation of children with elbow trauma. Studies like this corroborate this statistical improvement, in order to guarantee a better care and therapeutic approach necessary for the patient.

Keywords: Classification, diagnosis, fracture.

INTRODUCTION

Supracondylar fracture of the humerus (FSU) is typical of the immature skeleton¹, found especially in children, and represents a significant number of visits performed in

orthopedic emergency units. These fractures represent about 50%-60% of injuries that occur at the elbow level, with a predominance on the left or non-dominant side.

In most cases, these are complex fractures, sometimes complicated by neurovascular injuries, constituting about 60-75% of upper limb fractures in this age group.²

These situations are considered an orthopedic emergency, so their diagnosis is essential, and the time factor is crucial, being defined as the maximum period of 12:00 in which the patient with an apparent vascular lesion must be intervened. Otherwise, vascular injury and concomitant edema lead to an increased risk of compartment syndrome, which can progress to Volkmann's ischemic contracture.²

Pre and postoperative neurovascular assessment is essential for the detection and evolution of ischemia.³ Within the physical assessment, there are several techniques used for the diagnosis of edema and lymphedema, they are limb perimetry at different points, and volumetric measurements, obtained by submerging the limb in a cylinder with water or by the estimated volume through the circumference. of the member.⁵

The method of perimetry stands out, of easy reproducibility and execution, where circumference measurements of the limb (perimetry) are carried out at fixed points of the limb, always comparing the evaluated limbs bilaterally.⁵

Regarding the mechanism of trauma, fractures occurring in extension, with dorsal deviation, represent about 97% of cases followed by fractures in flexion that are more rare.

The classification most used for such a fracture is the one described by Gartland, proposed for fractures in the extension mechanism and based on the deviation of the coronal plane on radiographs of the elbow.

Type I: no or minimally displaced and with the anterior humeral line intact. Type II: small deviation, the fragments are kept in contact (intact posterior cortex), Type III: complete separation of the fragments (posterior cortical lesion)¹

In terms of treatment, the therapeutic indication is mainly based on the Gartland type I classification: the treatment chosen is conservative and there is no need for reduction, but an axillopalmar immobilization is chosen to be used for four weeks. In type II, there is a difference of opinion among orthopedists regarding the most effective treatment, conservative or surgical methods. When fractures fall into type III, treatment is surgical and based on closed reduction associated with osteosynthesis with Kirschner wires.

JUSTIFICATION

The justification for the chosen theme arises from the interest of the orthopedic team, considering the high prevalence of supracondylar fractures of the infant elbow in emergency care in the orthopedic traumatology shift and the importance of adequate assessment and diagnosis of these fractures, that are related to several acute and chronic complications. This project seeks to expand the area of knowledge in orthopedics, through the presentation and discussion of data, seeking the best therapy, especially for pediatric patients.

Considering that the supracondylar fracture of the humerus in children represents a significant number of consultations performed in orthopedic emergency units, this research aims to classify the fractures registered and treated at the Santa Casa service, a tertiary service, and to perform a comparison between the perimetry of the affected limb, and the contralateral limb.

From the statistics collected, propose

data that can increase the accuracy and importance of the physical examination, especially the perimetry, in the context of the very important supracondylar fractures of the immature skeleton.

GOALS

The main objective of this work is to evaluate the correlation between changes in perimetry of the fractured elbow and contralateral elbow with the Gartland classification for supracondylar humerus fractures in children. Such correlation will be studied based on the analysis of changes in the perimetry of the fractured elbow and contralateral elbow in children diagnosed with supracondylar fracture of the humerus treated in the emergency department of the orthopedics service of Santa Casa de Franca.

METHODOLOGY

An epidemiological and descriptive study with a quantitative approach was carried out, with data collection initiated after the evaluation of the Ethics Committee for the Analysis of the Research Project of the hospital itself through the online system of Plataforma Brasil (CAAE 52540721.6.0000.5438). Considering the confidentiality maintained by the epidemiological research, a Free and Informed Consent Form will be requested prior to the application of the questionnaires. Clinical and epidemiological aspects of pediatric patients who presented for care in the trauma-orthopedic emergency room with a supracondylar fracture were analyzed.

The study was carried out in a tertiary-level general hospital, part of the city's emergency medical care system. For data recording, a form containing epidemiological and clinical data was used, which has the following items: age, gender, affected side, time from trauma to arrival at the service, Gartland classification, perimetry of the fractured side.

Most of the data mentioned above are routine in child orthopedic care, except the perimetry of the fractured side, which is presented as an exclusive data to compose the research. The Microsoft Office Excel program was used to perform the statistical calculations. The results were expressed in previously prepared statistical graphs, using means and percentages.

RESULTS AND DISCUSSIONS

Data related to clinical and radiological evaluation of 33 children who were diagnosed with supracondylar humerus fracture were included in this study. The mean age of the children included in this study was 5.3 years, which corroborates the average age expressed in the literature, which is 5 to 7 years old (Mafulli & Cheng, 2001). The age range of incidence of these pediatric fractures may differ in the literature, being sometimes wider ranging from 3 and 10 years of age with a peak at 6 years.⁶

Graph 1 expresses the laterality of the fractures included in this study, and it can be observed that the higher prevalence of fractures in the left upper limb, reaching 52% of cases against 48% of occurrences on the right side. This result also corroborates data from the literature in which fractures on the left side and on the non-dominant side are the most common.¹¹

The time between the trauma and the care provided at the specialized orthopedic center varied between the group of children who were ideally seen in the first six hours after the trauma (24), children seen between 6 and 12 hours after the trauma (4), 12 to 24 hours after the trauma (3) and only two of the 33 children included in this study were seen after 24 hours of the trauma. In the literature, there are discussions about the importance of early surgical treatment with less time

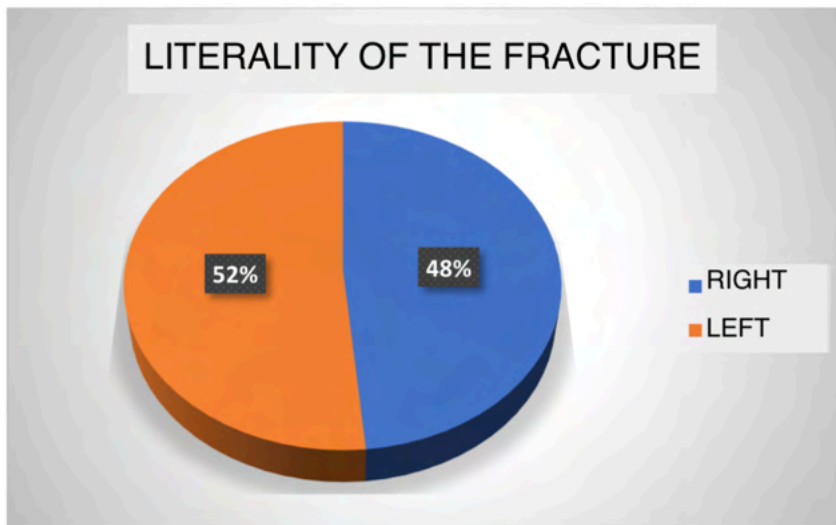
between trauma and surgery, which would be related to fewer complications and better postoperative results. (Graph 2).⁹

Children's supracondylar humerus fractures were classified using the Gartland classification, a classification widely used in this subtype of fractures of the infantile skeleton. Most fractures were classified as type 1 (49%) followed by type 3 fractures (18%) and type 2 fractures (33%) as expressed in Graph 3. In comparison, a similar Brazilian study included 63 children finding 8% of type 1 fractures, 17% of type 2 and the majority (74.6%) of type 3, which differs from the present study in which the most prevalent were type 1 fractures without displacement.¹²

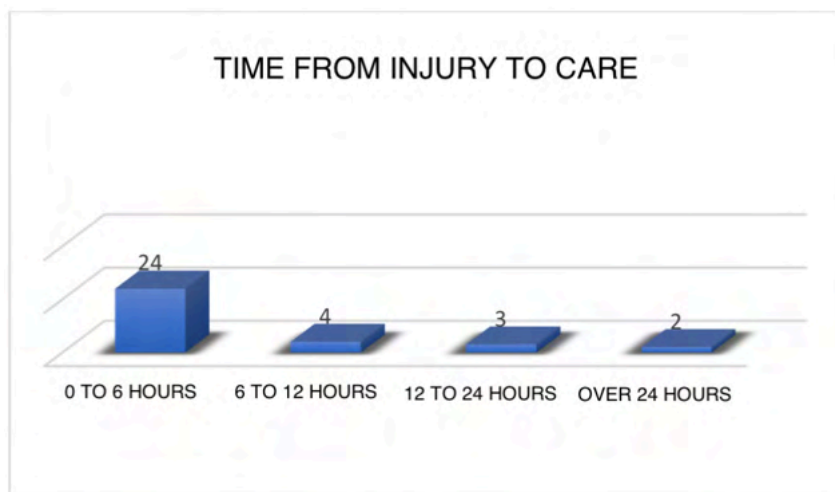
Perimetry performed at 3 different points on the upper limb affected by the fracture was compared with the perimetry on the uninjured side. The results indicate that the greatest difference in comparative perimetry occurred at the height of the joint line, with an average difference of 3.09 cm. The second largest difference between the perimetry of the injured side and the intact side occurred at the measurement of 2 centimeters below the joint line and had a mean of 2.28 centimeters. Finally, the smallest perimetry discrepancy occurred in the measurement parameter above the joint line and was 1.18 cm (Graph 4).

Considering only the fractures classified as type 1 Gartland, the greatest difference in perimetry also occurred at the height of the joint line (1.65 cm) followed by the region distal to the joint line (1.18 cm) and 0.62 cm when compared the perimetry in the proximal region of the joint line. (Graph 6).

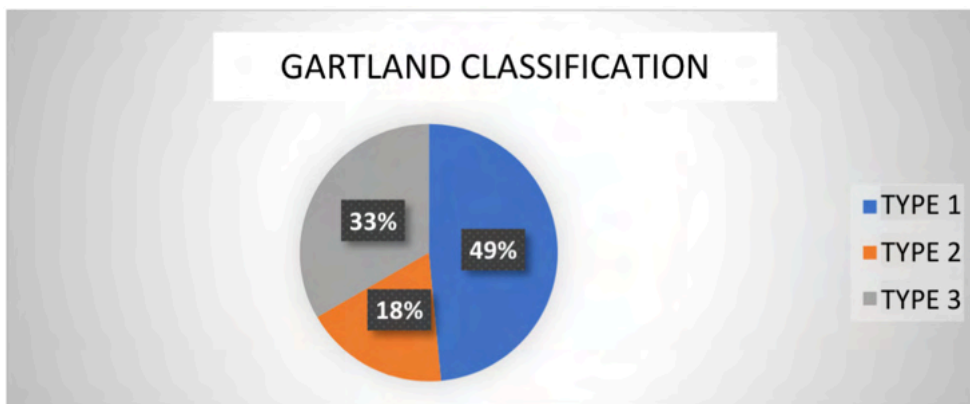
In type 2 Gartland fractures, corroborating the other measurements, the region with the greatest difference in perimetry occurred in the joint line (3.5 cm) as well and was greater than in type 1 fractures. (Graph 7).



Graph 1. Source: Own Author.

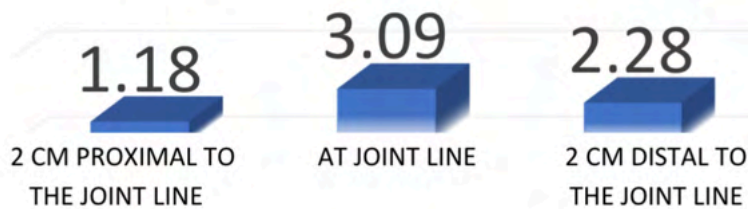


Graph 2. Source: Own Author.



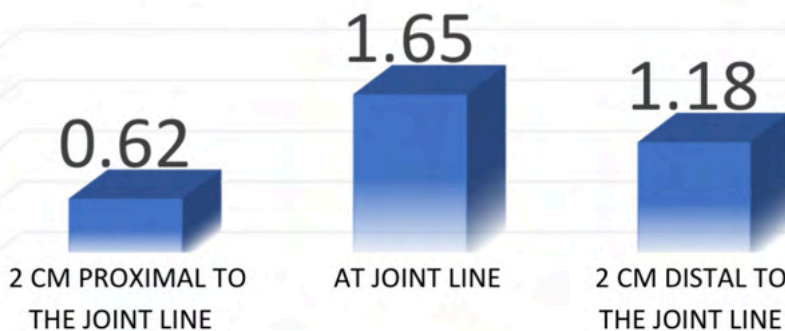
Graph 3. Source: Own Author.

DIFFERENCE IN PERIMETRY BETWEEN THE FRACTURE SIDE AND THE CONTRALATERAL SIDE INCLUDING ALL FRACTURES




Graph 4. Source: Own Author.

**GARTLAND TYPE 1
DIFFERENCE IN PERIMETRY BETWEEN THE SIDE OF THE FRACTURE AND THE CONTRALATERAL**

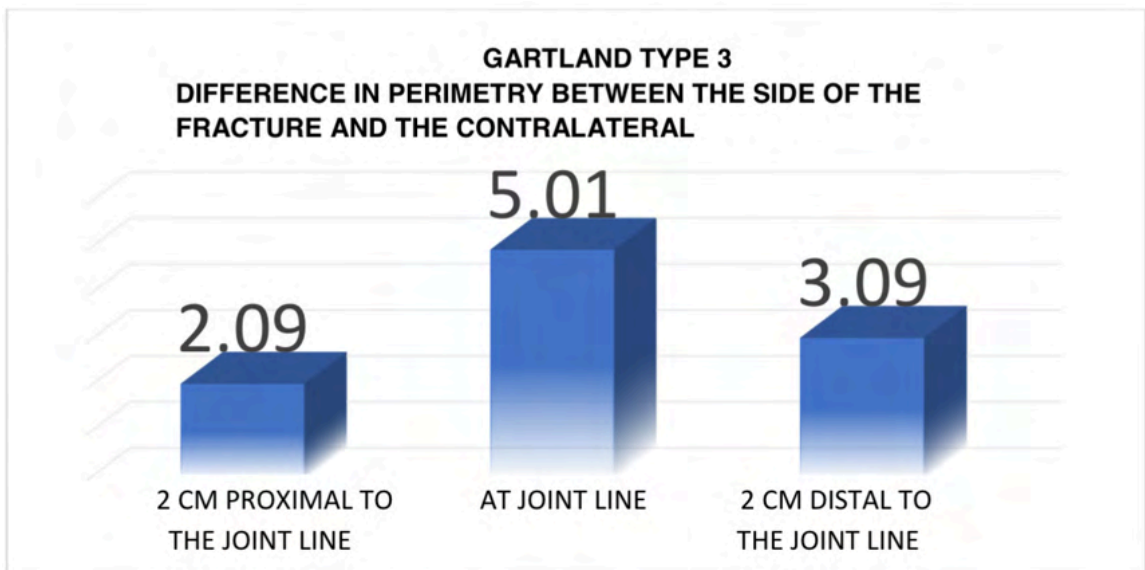


Graph 5. Source: Own Author.

**GARTLAND TYPE 2
DIFFERENCE IN PERIMETRY BETWEEN THE SIDE OF THE FRACTURE AND THE CONTRALATERAL**



Graph 6. Source: Own Author.



Source: Own Author.

The largest difference observed in the entire study was 5.01 cm and was measured at the height of the joint line of fractures classified as type 3 gartland in which there is a lesion of the two supracondylar bone corticals of the humerus with deviation. (Graph 8).

FINAL CONSIDERATIONS

Upon reaching the conclusion of the present article, we observed a greater difference in perimetry in fractures of greater severity. The results point to an increase in the difference in soft tissues measured by perimetry directly proportional to the increase in the Gartland classification, that is, the higher the classification, the greater the difference in perimetry.

This data can help the orthopedist and even the pediatrician in the initial evaluation of children with trauma that affects the elbow. In the case of larger perimetry differences, around 3 cm approximately, it can be predicted that the fracture that

affected the child, if diagnosed as a supracondylar fracture, has a high probability of corresponding to a type 2 gartland fracture or 3.

More studies, including a greater number of cases and with statistical improvement, may propose an index that correlates a greater difference in perimetry with the diagnosis of more severe supracondylar fractures.

REFERENCES

1. Patriota GSQA, Filho CAA, Assunção CA. **Qual a melhor técnica para fixação no tratamento de fraturas supracondilar do úmero em crianças?**. Rev Bras Ortop. 2017;52(4):428-434.
3. Carvalho, R, Fernandes H, Brito J, Fernandes P, Monteiro J. **Fratura Supracondiliana do Úmero complicada de lesão vascular**. Rev Port Ortop Traum. 2011;21(1):77-83.
4. Monarca F, Villacreses C, Escalda C, Lopes NC. **Complicações vasculares nas fraturas supracondilianas do úmero na criança**. Rev Bras Ortop. 2011;19(2):147-152
5. Moreira RFG, Nishimi AY, Zanon EM, Rama TS, Ciofi RPL, Dobashi ET. **Estudo Transversal sobre o tratamento das fraturas supracondilianas do úmero na infância dos tipos Garthland II e III: opinião do ortopedista brasileiro**. Rev Bras Ortop. 2018;53(2):129-135
6. Assunção CAA, Veloso RP, Akkari M, Santilli C. **Desvios Rotacionais na Fratura Supra Condiliana do Úmero em Crianças**. Novo Método de Avaliação Rev Bras de Cacerologia. 2011;46(4):45-50.
7. Rocha ITS, Faria AS, Filho CF, Rocha MA. **Reprodutibilidade das classificações AO/ASIF e Gartland para fraturas supracondilianas de úmero em crianças**. 2015;50(3):266-269.
8. Soni JS, Valenza WR, Schelle GC, Berri D, Pavelec AC. **Cotovelo Flutuante em Crianças**. Rev Bras Ortop. 2011;46(4):51-5.
9. Martini RK, Fonseca GF, Martini RK, Filho MA, Serafini OA. **Análise de fraturas supracondilianas do úmero em crianças**. Acta Ortop Bras. 2002;10(2):25-30.
10. Poggiali P, Nogueira FCS, Nogueira MPM. **Manejo da fratura supracondiliana do úmero na criança**. Ver Bras Ortop. 2020;():7-23.
11. Havráněk P, Pešl T, Hendrych J, Kučerová M. **Supracondylar fracture of the humerus in childhood**. Rozhl Chir. 2018 Spring;97(3):122-127.
12. Abzug JM, Herman MJ. **Management of supracondylar humerus fractures in children: current concepts**. J Am Acad Orthop Surg. 2012 Feb;20(2):69-77.