

**TREATMENT OF  
PATIENTS WITH  
LARGE AND COMPLEX  
INCISIONAL HERNIA  
WITH MODIFIED  
COMPONENT  
SEPARATION  
TECHNIQUE AND LONG-  
TERM FOLLOW-UP**

---

*Leonardo Araújo Carneiro da Cunha*

<http://lattes.cnpq.br/4335142041365432>

*Gabriel Schnitman*

<http://lattes.cnpq.br/8161022330458289>

*Acirio Ferreira Saraiva*

<http://lattes.cnpq.br/1640615196370357>

*Antônio Frederico Muricy de Farias*

<http://lattes.cnpq.br/1883495426480109>

*Danilo César Borges Pereira*

<http://lattes.cnpq.br/7703238076130577>

*Felipe Borges Pitangueira*

<http://lattes.cnpq.br/9611395785796181>

*Leandro Feliciano Nery dos Santos*

<http://lattes.cnpq.br/2494062602437447>

All content in this magazine is licensed under a Creative Commons Attribution License. Attribution-Non-Commercial-Non-Derivatives 4.0 International (CC BY-NC-ND 4.0).



**Abstract: Purpose:** For the treatment of large incisional hernias (LIH), one of the most performed procedures is the Anterior Component Separation (ACS). This study aims to analyze the results of a group of patients with complex and LIH who underwent hernia repair with a modified ACS technique, with a minimum two-year follow-up. **Methods:** Between January 2017 to June 2019, we selected patients with CIH undergoing open modified ACS hernia repair in a single center. In all cases, a polypropylene mesh was used in onlay position. All data was collected prospectively and focused on identifying post-operative results and risk factors associated with recurrence. **Results:** We analyzed 31 cases (Average age of xx years old, with xx% men and xx% woman), Over 50% of patients were obese. The mean defect size was 12cm on CT-scan and 48% of patients presented with loss of domain. Primary midline closure was obtained in 83.9% of cases using this technique, with 9.7% of patients requiring visceral reduction. Surgical site occurrence was found in 42% of cases, the most common being wound infection. Reoperation was required in 6.5% of cases and hospital readmission in 9.7%, with a mean hospital stay of 9.3 days. Recurrence rate was 6.5% after a mean follow-up of 25 months. **Conclusions:** This study reports positive results with a modified ACS for CIH. This open technique presents similar results to other approaches, with recurrence rates below those identified in other studies. Surgical times, complication rates and hospitalization times were comparable to those found in previous publications. For hernias with loss of domain, this technique can be performed in association with progressive pneumoperitoneum or botulinum toxin, which results in satisfactory primary closure rates.

**Keywords:** Large incisional hernia, Complex incisional hernia, Component Separation

Technique, Modified Anterior Component Separation.

The recurrence rates after repair of CIH can vary from 1.5% to 52%, even with the use of mesh [5]. Despite many studies in the literature, there is still no consensus regarding the best surgical treatment [4]. This choice takes into account the technical skill of the operator, technological availability, the possibility of better-quality prostheses and the institution's economic resources [5]. For the treatment of a CIH, one of the most performed procedures is the Anterior Component Separation Technique (ACS). Proposed in 1990 by Ramirez et al., TSCA presented a medial advancement of myofascial flaps to reconstruct the midline without tension [6]. The objective was to promote the release of the external oblique muscle (EOM) in addition to making an incision in the posterior sheath of the rectus abdominis muscle (RAM). The technique provides for the closure of major defects by functional transfer of components of the abdominal wall without the need to remotely transpose free muscle flaps [6]. However, these results are associated with complications generated by large flap dissections, which predispose to SSOS, such as seroma, infection, wound dehiscence and a higher recurrence rate [1, 3, 5, 7].

The ACS technique has received several changes over the years, such as that described by Carbonell et al. in 2009, where he used a large mesh positioned between the oblique muscles and placed the EOM flap on the abdominal wall over the screen [8]. This technique allowed a reduction of the dead space, limiting the subcutaneous dissection to the incision site on the EOM aponeurosis and achieving abdominal closure with reconstruction of the biomechanics of the abdominal wall. Thus, the technique proved to be useful for the management of CIH, with

low morbidity and decreased post-surgical complications [8].

Despite possibly presenting higher rates of infection of the abdominal wall and mesh when compared to the Posterior Component Separation Technique (PCS) with the transverse abdomen muscle release (TAR), studies demonstrate that the ACS presents outcomes comparable to PCS in the repair of complex abdominal wall defects [9, 10]. Many other changes to the ACS technique have been suggested, but the results presented by the studies are heterogeneous, notably in terms of the recurrences rates and post-surgical complications. In 2017, Torregrosa et al. presented a 10-year follow-up study in which a modified protocol for ACS was used [2]. The approach used a mixed technique, associating the ACS with the use of preoperative progressive pneumoperitoneum (PPP) or chemical separation of the components through the use of botulinum toxin type A (BTA) in the preoperative period of patients who had complex hernias with loss of home and volume ratio greater than 20%.

The aim of the present study is to analyze the postoperative results and recurrence of a group of patients with CIH who underwent hernia repair with a modified ACS technique, with a minimum of two-year follow-up.

## **METHODOLOGY**

### **STUDY DESIGN AND PARTICIPANTS**

This is a retrospective case series study with CIH patients undergoing surgical hernia repair by a modified ACS technique, in a single center, between the years 2017 and 2019. All patients had a clinical follow-up and tomographic evaluation, for a minimum period of two years after surgery. The study was approved by the ethics and research committee and all patients signed an informed consent form.

The inclusion criteria for the study were patients with midline CIH, who had an intraoperative transverse defect measurement greater than 10 cm or defects smaller than 10 cm who were unable to have an abdominal wall closure without tension. Data were collected retrospectively from hospital admission to postoperative follow-ups. The treatment was carried out by the same surgical team and the postoperative follow-up was on at outpatient clinics on the 7th postoperative day, in the first month and every 3 months, during the first postoperative year. From the second year onwards, evaluations were performed every six months, and all cases underwent routine abdominal computed tomography (CT) annually. During medical follow-ups, in the face of clinical evidence or patient's report of a possible recurrence, a CT scan was performed to confirm the diagnosis.

For this study, the concept of loss of domain (LD) was defined by the clinical examination, when the examiner was unable to reduce partially or totally the herniated contents to the abdominal cavity with the patient at rest in the supine position, with hands on the head and lower limbs flexed. All patients with these characteristics underwent a CT scan for volumetric and abdominal wall study. The calculation of the volume of the hernial sac, the volume of the abdominal cavity and the volumes ration followed the methodology described by Tanaka et al. [11]. When the volumes ration was greater than 25% or the patient had "complex defects" (i.e., cases with LD and tomographic measurement greater than 15 cm associated with an "absence" of the wall) and/or multiple previous relapses (more than three times), were submitted to a PPP protocol with daily insufflation of 2000 mL of room air, divided into two 1000 mL sessions, for up to 14 days.

## **SURGICAL TECHNIQUE (MODIFIED ACS)**

Initially, the scar was removed, with dissection around the entire defect, followed by the opening of the hernial sac and release of adhesions with the abdominal wall. We identified the lateral limits of the RAM from the peritoneal aspect, proceeding with the dissection of the pre-aponeurotic space and advancement of up to 1-2 cm beyond the lateral border of the RAM. This procedure effectively detached the minimal space necessary to avoid extensive dissections and devascularization of the skin. Subsequently, a vertical incision was made in the entire aponeurosis of the EOM, exactly 1-2 cm lateral to the lateral border of the RAM, from 3-4 cm above the costal margin to the external inguinal ring. Dissection began through the space between the EOM and the internal oblique muscle (IOM), up to the level of the posterior axillary line. At that point, we evaluated whether a tension-free approach of the midline was achievable. Then, we performed the wall closure with continuous suture, a stage which we would denominate Level I closure. When the suture was not achievable or when performed under great tension, we added an incision in the posterior aponeurosis of the RAM, with dissection through the retromuscular space to the semilunar line, to add an estimated gain of 2 to 3 cm on each side. We reevaluated the approach of the midline and called it Level II if we considered the closure as adequate. If, after using Levels I and II, the closure could not be performed, we used part of the hernial sac to reconstruct the abdominal wall, with resection of its excess. When necessary, this step defined bridging cases and could be necessary due to the size of the defect or due to the format or location of the defect, even in cases with defects smaller than 10 cm, such as suprapubic hernias or those with important fibrosis.

In all cases, a polypropylene mesh was used, positioned onlay and between the MOE and MOI, where the MOE incision was made, up to the level of the middle axillary line. (**Figure 1**) The prosthesis was positioned with its limits superiorly at the subxiphoid region and the subcostal margins, laterally at the middle axillary lines, and inferiorly at the inguinal ligaments and pubic symphysis. The MOE flap was sutured continuously over the mesh and the anterior aponeurosis, restoring the anatomy of the lateral abdominal wall. After this step, we made another continuous suture line over the mesh in the central region of the aponeurosis (**Figure 2**). When bridging was performed, the position of the mesh followed the same anatomical limits as mentioned before, covering the hernial sac. The subcutaneous tissue was sutured as per the Baroudi technique [12]. Suction drains were placed in the subcutaneous space. All drains were removed after the 7th postoperative day when the daily output was less than 50mL in 24 hours.

## **DATA COLLECTION**

All data was collected prospectively and maintained in a password-protected online database. The data collected were: sex; age; body mass index (BMI); American Society for Anesthesiology Physical Status Classification System (ASA) score; comorbidities (obesity, hypertension, diabetes, pulmonary disease, cancer and immunosuppression); Severity Of Comorbidity (SOC) score [13]; and hernia-related surgical history. Regarding the characteristics of the hernia, the following data were collected: characteristics of the symptoms; duration since the initial symptoms; and length of time until the hernia appeared or the last recurrence. To stratify the risk of wound complications, we used the modified Ventral Hernia Working Group classification [14, 15]. Among the criteria

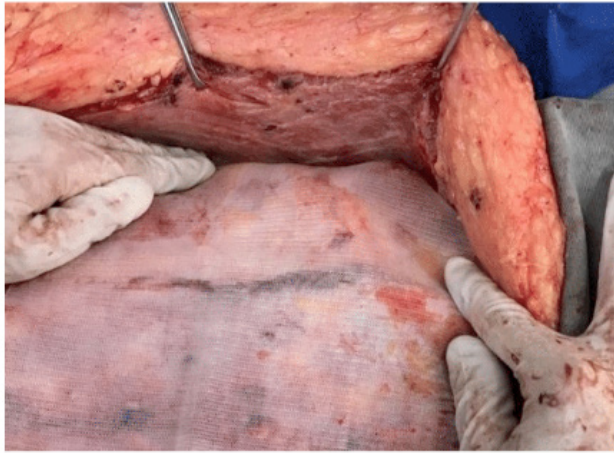


Figure 1: Positioning the screen between the MOE and MOI.

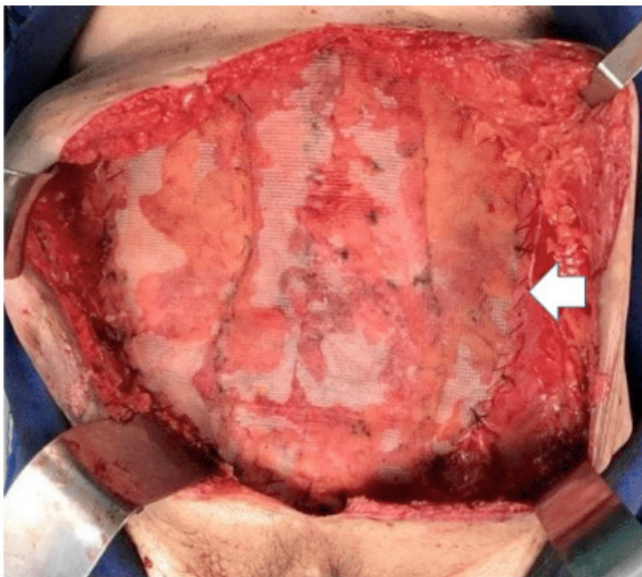


Figure 2 -Final aspect of the prosthesis in the central region of the abdomen. White arrow: fixation of the EOM flap over the mesh and anterior aponeurosis

for classifying the defect, we analyzed the history and number of recurrences, the largest transverse diameter of the defect (measured by CT scan) and the location of the medial component, following the recommendations of EuraHS [13]. The intraoperative data analyzed were: surgical time (in minutes); transversal, longitudinal (in cm) and area (in cm<sup>2</sup>) of the defect; procedures and associated complications; type of closure of the anterior aponeurosis after using the ACS at three levels (level I, level II or bridging); and degree of surgical contamination according to the CDC classification [16].

All changes related to the surgical site were called SSO and were considered if happened within the period of up to 30 days after surgery. Among the possible SSOs, the following stand out: surgical site infection, seroma, hematoma, ischemia or skin necrosis, wound dehiscence and enterocutaneous fistula. If the patient had more than one type of SSO, these data were added up and accounted for separately. All postoperative complications were stratified according to the Clavien-Dindo score [17]. Recurrence was defined based on clinical examination and confirmed with a CT scan.

## STATISTICAL ANALYSIS

For descriptive statistical analysis, the distribution of variables was verified using the Shapiro-Wilk and Kolmogorov-Smirnov tests. For normal distributions, mean and standard deviation (SD) were used, and for variables with abnormal distribution, median and interquartile range (IIQ). All tests were performed using the IBM SPSS STATISTICS software, version 26.

At postoperative was identified the SSO frequency of 41,9%. Among those complications, the surgery's site infection was 29% what represents 9 cases and the clinical repercussions with seroma in 9,7%,

## RESULTS

The data of 31 patients who underwent hernia repair by the modified ACS, from January 2017 to May 2019, were analyzed.

The sample had an average age of 55.6 years and the distribution between the genders was similar. The patients' mean BMI was 29.76 ( $\pm 5.84$ ) kg/m<sup>2</sup>. Obesity and cancer were the most common comorbidities among patients, both identified in 51.6% of patients, while arterial hypertension was present in 48.4% of patients. **Table 1** summarizes the most relevant epidemiological findings.

At the time of hospital admission, the average duration of symptoms reported by patients was 24 ( $\pm 21$ ) months. The mean time since the onset of the hernia or the last recurrence was 8.4 ( $\pm 7$ ) months, and 9 (30%) cases had a previous recurrence. Most patients had had one or two recurrences (29% and 12.9%, respectively). The surgery most commonly associated with the origin of the hernia was a previous hernia repair (29% of cases), followed by appendectomy (16.1%) and hysterectomy (9.7%). Most hernias were found in zone M2-M4 (29%) or M3-M4 (25.8%). The average defect size identified by tomography was 12,00 cm. Most cases were classified as W3 (77.4%). **Table 2** shows the details of the characteristics of the hernias in the sample.

The mean measurement of the transverse, longitudinal and area of the defect identified intraoperatively was 14 cm, 20 cm and 257.2 cm<sup>2</sup>, respectively. It was possible to perform primary closure in 26 cases (83.8% of the total). There was a need to perform visceral reduction in three patients (9.7%) who had LD and in which cases complete reduction of the hernial content to the abdominal cavity during the operation was not achieved. A summary of the intraoperative data is shown in **Table 3**.

At postoperative was identified the SSO frequency of 41,9%. Among those complications, the surgery's site infection was 29% what represents 9 cases and the clinical repercussions with seroma in 9,7%,

Population characteristics	Sample (n = 31)
Age (mean)	55,6 (±14,6)
Gender	
<i>Female</i>	15 (48,4%)
<i>Male</i>	16 (51,6%)
BMI	29,76 (± 5,84)
<i>Smoking</i>	5 (16.1%)
Comorbidities	
<i>Obesity</i>	16 (51,6%)
<i>Hypertension</i>	15 (48,4%)
<i>Diabetes</i>	3 (9,7%)
<i>History of Cancer</i>	3 (9,7%)
<i>Others*</i>	3 (16.1%)
ASA Score**	
<i>ASA I</i>	10 (32,3%)
<i>ASA II</i>	20 (64,5%)
<i>ASA III</i>	1 (3,2%)
SOC score[13]***	
0	9 (30%)
1	17 (56.7%)
2	3 (10%)
3	1 (3.3%)
Previous surgery	
<i>Elective</i>	11 (35,4%)
<i>Emergency</i>	20 (64,5%)

\*Other comorbidities: Chronic renal failure; Asma; e Immunosuppression.

\*\*ASA score: ASA 1 - Normal patient with no disease; ASA 2 - Mild systemic disease, with no impact on daily life; ASA 3 - Severe systemic disease that limits daily activities.

\*\*\*SOC score: EuraHS Severity Of Comorbidity Score 0 - no comorbidity; Score 1 - asymptomatic; Score 2 - stable disease, intermittent therapy and medical consultation needed ≤4x/year; Score 3 - stable disease, continuous therapy with regular medical consultation >4x/year; Score 4 - progressive disease, with changing or intensified therapy and frequent medical >12x/year

Table 1. Study population's characteristics.

<b>Preoperative data</b>	<b>Sample (n = 31)</b>
Duration of the symptoms (in months)	24 ( $\pm$ 21)
<b>Main symptoms</b>	
<i>Pain</i>	28 (90,3%)
<i>Bulging</i>	13 (41,9%)
<i>Nausea/vomiting</i>	4 (12,9%)
<i>History of intestinal obstruction</i>	1 (3,2%)
Time until the recurrence (in months)	8,4 ( $\pm$ 7)
<b>Previous surgery related to the hernia</b>	
<i>Incisional hernia repair</i>	9 (29%)
<i>Appendectomy</i>	5 (16,1%)
<i>Exploratory laparotomy due to trauma</i>	4 (12,9%)
<i>Total hysterectomy</i>	3 (9,7%)
<i>Cesarian section</i>	2 (6,5%)
<i>Proctosigmoidectomy</i>	2 (6,5%)
<i>Hemicolectomy</i>	2 (6,5%)
<i>Gastrectomy</i>	1 (3,2%)
<i>Prostatectomy</i>	1 (3,2%)
<i>Others*</i>	2 (6,5%)
<b>Number of previous recurrences</b>	
<i>1</i>	4 (12,9%)
<i>2</i>	2 (6,5%)
<i>3</i>	1 (3,2%)
<i>4</i>	2 (6,5%)
<b>Modified VHWG Grading [14]**</b>	
<i>Grade I</i>	7 (22,5%)
<i>Grade II</i>	21 (67,8%)
<i>Grade III</i>	3 (9,7%)
<b>Classification related to the midline component***</b>	
<i>M 3</i>	3 (9,7%)
<i>M 5</i>	1 (3,2%)
<i>M 1 – M 2</i>	1 (3,2%)
<i>M 1 – M 4</i>	3 (9,7%)



M 2 – M 3	3 (9,7%)
M 2 – M 4	9 (29%)
M 3 – M 4	8 (25,8%)
M 4 – M 5	3 (9,7%)
Classification related to the hernia defect size (mean)****	
W 2	7 (22,6%)
W 3	24 (77,4%)
Hernia defect size on CT-scan (in centimeters)	12,0 (10,1 – 13,5)
Loss of domain	15 (48,4%)
Volumes ratio (mean)	0,27 (0,2 IIQ)
Use of PPP	10 (33,3%)

\*Others: Cystostomy e nephrectomy

\*\*Modified VHWG Grading: Modified Ventral Hernia Working Group Grade I - Low risk of SSO, no comorbidity or history of wound infection; Grade II - Associated comorbidity; Grade III - Potentially contaminated surgical site, with history of infection, stoma or gastrointestinal leakage.

\*\*\*Classification related to midline: M1 - Subxiphoid; M2 - Epigastric; M3 - Umbilical; M4 - Infra-umbilical; M5 - Supra-Pubic.

\*\*\*\*Classification related to hernia defect size: W1 - <4cm; W2 - 4 to 10cm; W3 - >10cm.

Table 2. Preoperative data of the study's sample.

Intra-operative data	Sample (n = 31)
Measurements of the hernia defect (in centimeters)	
<i>Width</i>	14 (11,5 – 16,5)
<i>Length</i>	20 (15 – 21)
<i>Area (cm<sup>2</sup>)</i>	257,2 (±109)
Concomitant procedures	
<i>Abdominoplasty</i>	19 (61,3%)
<i>Appendicectomy</i>	8 (25,8%)
<i>Adhesiolysis</i>	8 (25,8%)
<i>Enterectomy</i>	4 (12,9%)
<i>Cholecystectomy</i>	2 (6,4%)
<i>Hysterectomy</i>	1 (3,2%)
<i>Mesh removal</i>	1 (3,2%)
<i>Resection of enterocutaneous fistula</i>	1 (3,2%)
<i>Colectomy</i>	1 (3,2%)
<i>Reconstruction of intestinal continuity</i>	1 (3,2%)
Surgical complications	
<i>Small intestine injury</i>	3 (9,7%)
<i>Colon injury</i>	3 (9,7%)
<i>Bladder injury</i>	1 (3,2%)
<i>Stomach injury</i>	1 (3,2%)
<i>Visceral reduction</i>	3 (9,7%)
Type of abdominal wall closure*	
<i>Primary</i>	26 (83,9%)
<i>Level II</i>	14 (41,1%)
<i>Level I</i>	12 (38,7%)
<i>Bridge</i>	5 (16,1%)
Surgical time (in minutes)	208,97 (±80 IIQ)

\*Type of wall closure: Level I - Direct suture and midline reconstruction after incision and release of the EOM; Level II - suture and midline reconstruction after incision and release of the EOM + posterior aponeurosis of the RAM up to the semilunar line; Bridge - Use of the hernia sac for anterior closure.

Table 3. Intra-operative data.

what means 3 cases. Two patients required reoperation: one patient due to intestinal obstruction to early adhesions; the second patient for abdominal compartment syndrome. Despite the number of cases with SSI, all patients were successfully treated with antibiotics and surgical debridement. No patients required mesh removal. The data for the postoperative period are detailed in **Table 4**.

The average length of hospital stay was 9.3 days. However, when we exclude the 14 days of PPP, the average time after the hernia repair is reduced to 4 days. In outpatient follow-up, two patients presented recurrence, one in the 9th and another in the 10th postoperative month. Both were obese, evolved with deep infection of the abdominal wall and required readmission to treat the condition. At the end of the follow-up of this study, the recurrence rate was 6.45% after an average follow-up period of 25 months.

## DISCUSSION

Incisional hernias are challenging conditions for surgeons, especially when associated with LD and multiple previous surgeries with recurrences. The ideal reconstruction of the abdominal wall should obey well-established fundamentals such as the promotion of a tension-free repair, the preservation of the neurovascular bundle and the maintenance of the abdominal wall muscular anatomy with normalization of the physiology [18]. For that purpose, ACS is useful in the repair of CIH and has been frequently used by surgeons, however, despite the wide use of this technique, the literature still describes important complications associated with this surgery in up to 50% of cases and postoperative mortality reaching 1.3% [4]. Common problems related to this technique are wound infections or flap necrosis, seroma and hematoma, all resulting mainly from the

loss of perforating arteries due to the extensive dissection of subcutaneous tissue [4, 19]. In order to add new technical options for the vascular preservation of perforating arteries, several surgical variations of the component separation technique have been developed in the last two decades. These modifications have often been used according to the complexity and size of the hernia [20]. For example, in 2002, Saulis and Dumanian described the technique for preserving periumbilical perforators and this technique has been widely discussed as a good alternative to avoid SSOs [21].

Currently, the most used ACS variations are as follows: open anterior separation, as described by Albanese and Ramirez et al.; anterior laparoscopic approach, according to Rosen et al.; and lastly, an open anterior approach with preservation of perforators, as described by Saulis and Dumanian [20]. In our department, we use the TSCA adding modifications proposed by Carbonell et al. and Torregrosa et al. [2, 8]. This technique requires less dissection of the subcutaneous tissue, limited laterally by the incisions of the aponeurosis of the EOM. This approach aims to preserve the vascularization of the skin flap and to position the mesh on the space between the EOM and the IOM, with a large lateral overlap. Our results corroborate the technical benefits obtained by the modification proposed by Carbonell et al., adding advantages of preoperative treatment using BTA and PPP in patients with large volume hernias [8]. The use of these elements as abdominal wall expanders has been widely described in the medical literature, with well-documented evidence of safety and viability [5, 22, 23]. The use of these preoperative adjuvants in giant hernias helps in surgery by increasing tissue expansion, which facilitates the abdominal wall closure and reduces rates of abdominal compartment syndrome [22, 23].

Postoperative data	Sample (n = 31)	Clavien-Dindo*
Surgical site occurrence (SSO)	13 (41,9%)	
<i>Wound infection*</i>	9 (29%)	
<i>Grade I</i>	3 (9,7%)	II
<i>Grade II</i>	1 (3,2%)	II
<i>Grade III</i>	5 (16,2%)	IIIA (2) / IIIB (3)
<i>Seroma</i>	3 (9,7%)	IIIA
<i>Necrosis of the skin</i>	1 (3,2%)	IIIA
Clinical complications		
<i>Pneumonia</i>	1 (3,2%)	II
<i>Pulmonary embolism</i>	1 (3,2%)	IV
<i>Prolonged ileus</i>	1 (3,2%)	II
<i>Acute coronary syndrome</i>	1 (3,2%)	IV
Reoperation	2 (6,5%)	
<i>Early adhesive bowel obstruction</i>	1 (3,2%)	IIIB
<i>Abdominal compartment syndrome</i>	1 (3,2%)	V
Hospital readmission	3 (9,7%)	IIIB
<i>Surgical wound debridement</i>	3 (9,7%)	
Mean length of stay in the ICU (in days)	5,3 (3 – 9)	
Mean length of hospital stay (in days)	9,3 (2 – 26)	
Mean hospital stay after PPP (in days)**	4 (2 – 15)	
Mean follow-up time (in months)	25,36 (24 – 48)	3
Recurrence	2 (6,45%)	

\*Clavien-Dindo Classification of Surgical Complications: Grade I - Complication with no need for specific intervention or pharmacological treatment; Grade II - Complication with a specific pharmacological treatment necessary; Grade III - Need for surgical intervention (a) without general anesthesia or (b) with general anesthesia; Grade IV: Organ failure (a) one organ or (b) multiple organs; Grade V - Death.

\*\*Mean length of hospital stay excluding the time needed for the PPP program (14 days).

Table 4. Immediate postoperative and follow-up data

Studies exploring the ACS technique with modifications have already been published in the medical literature, but they are mostly case series studies with large sample heterogeneity and present limited results due to the data collection process [9]. We analyzed 31 patients during an average outpatient follow-up period of 25.3 months. Although we present a small sample of patients, the follow-up of more than two years gives us confidence regarding the results produced by this technique. In addition, we presented a population sample with a similar demographic profile to that reported in the literature. Our study showed a mean age and prevalence between genders similar to previous studies [2, 5, 24]. We reported an average BMI of 29.76 kg/m<sup>2</sup>, while it varies between 27.3 and 33.6 kg/m<sup>2</sup> in the literature [2, 5, 19, 24]. Furthermore, the average width and length of the abdominal wall defect in our study were 14 and 20 cm<sup>2</sup>, which corresponds with results from previous studies that reported a variation in width from 13 to 15 cm and in length from 18 to 25 cm [2, 19, 24].

We performed 31 surgeries to correct an incisional hernia, with an average surgical time of 209 minutes, which is comparable to other surgical times presented previously [2, 5]. Most of our cases had an additional procedure performed, the most common being abdominoplasty (61%), followed by appendectomy and adhesiolysis, both in 25.8% of the cases. Additionally, three patients (9.7%) required visceral reduction with a right colectomy, to allow adequate closure of the abdominal wall. Torregrosa et al. reported additional procedures in 33% of cases, which included 7.1% of intestinal resections [2]. The visceral reduction performed in our cases allowed to obtain primary closure in 84% of cases with the technique used in this study. Similar results were reported by Maloney et al. with 89% of fascial closure and by Krpata

et al. with 91% [5, 10].

In eight patients (25.8%), there was some type of intraoperative surgical complication, with about half of those complications being lesions of the small intestine, colon or stomach. None of the surgical complications evolved to postoperative complications related to the original event. Maloney et al. reported an occurrence of intestinal injury in 6% of cases [5], while Torregrosa et al. described it in 4.8% of surgeries [2]. We also presented 6.5% rate of reoperations, comparable to the results informed in a meta-analysis by Hodgkinson with a 5.9% rate of the combined cases [9]. We reported an average hospital stay of approximately 9 days, practically the same as other studies using the same surgical technique [2, 5, 9]. In addition, our rate of readmission was 9.7%, while Maloney et al. presented hospital readmissions in 13% of cases [5].

One of the main postoperative complications of this surgery is due the need to create extensive subcutaneous flaps, which increases the risk of SSO. Rates of wound infection vary between 15 and 45% of cases [25]. In our study, the most common complication was wound infection, identified in almost 30% of patients. Maloney et al. reported a similar finding, with SSO occurring in 35.1% of their cases [5]. This data can be confirmed by the review by Cornette et al., where a 33.4% rate of wound complications was identified [20]. Likewise, de Vries et al. reported a 32.6% rate of SSO in the included patients [19]. Krpata et al. identified higher rates, reaching 48.2% of SSOs for patients in the ACS group [10]. Superior numbers were reported by Torregrosa et al., with SSO rates as high as 60% [2]. In contrast, the meta-analysis by Hodgkinson et al. presented an average rate of SSO in the included studies of 21.6% for superficial complications and only 12.7% for deep ones [9]. These rates are

relevant as there are indications that wound complications may be associated with the appearance of recurrences [5, 25]. In our experience, recurrences occurred exclusively in obese patients who had a deep wall infection. Maloney et al. presented evidence confirming that elevated BMI and wound complications are factors associated with hernia recurrence [5]. Giving the complication context, one patient studied evolved to mesenteric ischemia and septic shock, registering 1 case of mortality.

With the advent of minimally invasive surgeries, laparoscopic ventral hernia repair has become the method of choice for many surgeons, after its initial report in 1993 by LeBlanc et al. [26]. Several studies comparing open and laparoscopic surgery followed this innovation [18]. Lowe et al. reported on laparoscopic surgery for component separation in 2000, describing better results in sparing the vascularization of the wall when compared to open surgery [27]. Subsequently, Maas et al. improved the minimally invasive vascular preservation with the use of the dissection balloon in the avascular plane between the external and internal oblique muscles, instead of the subcutaneous space [28]. The use of the balloon between these muscles was even more popular after the implementation of the division of the EOM aponeurosis using the laparoscopic instruments in this space as described by Rosen et al. [29].

The choice between open and laparoscopic surgery remains an extensive debate that involves defining the benefits of each technique. A meta-analysis by Jensen et al. demonstrated that there is evidence that minimally invasive surgery promotes lower rates of SSO with similar rates of recurrence when compared to open surgery [30]. Other studies consistently demonstrate lower rates of SSO with laparoscopic surgery, although these do not limit their analyzes to CIH [31–

33]. The most recent review by Cornette et al. does not corroborate these results but points out that the presence of outlier studies may be benefiting open surgery [20]. However, Cornette et al. point to a higher rate of recurrence in open surgeries when compared to other techniques, which cannot be confirmed by the results identified by Jensen et al. [20, 30]. These findings may point to an absence of a causal relationship between the two outcomes; in that case, they would simply be findings common to the same patients.

Meanwhile, there is another aspect to consider when choosing laparoscopic or open hernia repairs. In our experience, more than 60% of patients underwent abdominoplasty in the same surgery as the hernia repair. This procedure is commonly necessary in these cases due to the tissue expansion resulting from the loss of domain, in addition to (sometimes) extensive scars resulting from multiple previous surgeries. Indeed, Maloney et al. reported panniculectomy in approximately 50% of the surgeries performed in his study [5]. In contrast, Torregrosa et al. performed this procedure in only 2.6% of cases [2]. Reinforcing the option of abdominoplasty concurrent with the hernia repair, there is no evidence of increased complications when performing both procedures at the same time [34]. On the other hand, evidences seems to show a reduced risk assumed by reducing hospitalizations and anesthesia with this choice [34, 35]. Considering these elements in favor of performing both procedures concomitantly, we believe that the benefits of laparoscopy in patients with CIH can be outweighed, at least partially, by the fact that open surgeries facilitate this strategy, and in many cases complex plastic reconstructions are necessary. In any case, modifications of the ACS such as the one we carry out should be encouraged in order to confer lower rates of SSO to open techniques, which can be a

relevant factor in the surgical recovery of patients [5].

Another timely discussion about the different surgical options of hernia repair arose when Carbonell et al. reported on PCS in 2008, and renewed doubts about the “gold standard” treatment for CIH [36]. More recently, Novitsky et al. described the TAR technique and reinforced its use as the best option for the myofascial advancement of the abdominal wall [37]. Malone et al. demonstrated evidence of a significantly better recurrence rate with PCS, a finding that was confirmed by Krpata et al. [5, 10]. However, an extensive review comparing PCS and ACS presented analyzes with no significant findings demonstrating any difference between the two techniques [9]. Despite evidence of similar outcomes with both techniques, experts remain divided about the best choice between the two options.

Studies using the ACS reported recurrence rates of 10 to 22% after a follow-up of 9.5 months to 4.5 years [1]. In our study, we reported a recurrence rate of 6.45% after an average follow-up time of 25.3 months, which represents a low number when compared to the literature. Similarly, Maloney et al. reported a 4.1% recurrence rate after a 23.3-month follow-up [5]. The recurrence rate of review studies such as that presented by Hodgkinson et al. and Cornette et al. were 9.5% and 3.4 to 7.6%, respectively [9, 20]. Furthermore, there is evidence that a longer follow-up time should lead to an increase in recurrence rates and many studies still have a follow-up time of less than two years [1, 20]. For example, de Vries et al. reported a recurrence rate of 32% after an outpatient follow-up of 15.6 months [19]. Krpata et al. identified a recurrence rate of 14.3% after an average follow-up of 56 patients for 9.1 months [10]. Finally, the meta-analysis carried out by Hodgkinson et al. included a total of 285 patients and identified a mean follow-up time of 14 months [9].

This confirms the results presented here as promising, considering the prolonged follow-up of the study.

**Table 5** (appendix) shows the main results obtained by different authors using ACS in various population samples, where the great diversity of options and evidence surrounding complex abdominal wall surgery is demonstrated. Within this context, the need to establish hospital centers dedicated to this pathology seems to be clear, as it promotes local protocols and develops surgical experience for the appropriate treatment of patients. There is evidence of a 50% reduction in complications and 60% in recurrence with the creation of centers specialized in complex hernias [5]. Additionally, it is possible to predict significant savings for the system, considering the significant benefits that would be achieved with these centers. This centralization in the health care network can bring important improvements.

This study has some limitations that must be considered. As a study without a control group, we do not propose to identify associations or establish comparisons between techniques from our results alone. This is a study that reaffirms the execution of a surgical technique modifying the established ACS and confirms data from the literature. In addition, this study presents a small sample size, which limits the possibility of analysis due to the low statistical power of the tests.

## CONCLUSION

This study reports positive results with the use of a modified component separation technique for the correction of complex incisional hernias. The use of this open technique presents results similar to other approaches, with recurrence rates below those identified in other studies, without an increase in the incidence of surgical wound complications. Relevant factors were

identified to validate the use of this technique, such as surgical times, complication rates and hospitalization times comparable to those found in previous publications. For hernias with loss of domain, this technique can be

performed in association with the use of progressive pneumoperitoneum or botulinum toxin, which results in satisfactory primary closure rates.

## REFERENCES

1. Pauli EM, Rosen MJ (2013) Open Ventral Hernia Repair with Component Separation. *Surg Clin North Am* 93:1111–1133. <https://doi.org/10.1016/j.suc.2013.06.010>
2. Torregrosa-Gallud A, Sancho Muriel J, Bueno-Lledó J, et al (2017) Modified components separation technique: experience treating large, complex ventral hernias at a University Hospital. *Hernia* 21:601–608. <https://doi.org/10.1007/s10029-017-1619-6>
3. Slater NJ, Montgomery A, Berrevoet F, et al (2014) Criteria for definition of a complex abdominal wall hernia. *Hernia J Hernias Abdom Wall Surg* 18:7–17. <https://doi.org/10.1007/s10029-013-1168-6>
4. Deerenberg EB, Timmermans L, Hogerzeil DP, et al (2015) A systematic review of the surgical treatment of large incisional hernia. *Hernia* 19:89–101. <https://doi.org/10.1007/s10029-014-1321-x>
5. Maloney SR, Schlosser KA, Prasad T, et al (2019) Twelve years of component separation technique in abdominal wall reconstruction. *Surgery* 166:435–444. <https://doi.org/10.1016/j.surg.2019.05.043>
6. Ramirez OM, Ruas E, Dellon AL (1990) “Components separation” method for closure of abdominal-wall defects: an anatomic and clinical study. *Plast Reconstr Surg* 86:519–526. <https://doi.org/10.1097/00006534-199009000-00023>
7. Sukkar SM, Dumanian GA, Szczerba SM, Tellez MG (2001) Challenging abdominal wall defects. *Am J Surg* 181:115–121. [https://doi.org/10.1016/s0002-9610\(00\)00566-3](https://doi.org/10.1016/s0002-9610(00)00566-3)
8. Carbonell Tatay F, Bonafé Diana S, García Pastor P, et al (2009) New surgical technique in complex incisional hernias: Component Separation Technique (CST) with prosthesis and new muscle insertions. *Cirugia Espanola* 86:87–93. <https://doi.org/10.1016/j.ciresp.2009.03.015>
9. Hodgkinson JD, Leo CA, Maeda Y, et al (2018) A meta-analysis comparing open anterior component separation with posterior component separation and transversus abdominis release in the repair of midline ventral hernias. *Hernia* 22:617–626. <https://doi.org/10.1007/s10029-018-1757-5>
10. Krpata DM, Blatnik JA, Novitsky YW, Rosen MJ (2012) Posterior and open anterior components separations: a comparative analysis. *Am J Surg* 203:318–322; discussion 322. <https://doi.org/10.1016/j.amjsurg.2011.10.009>
11. Tanaka EY, Yoo JH, Rodrigues AJ, et al (2010) A computerized tomography scan method for calculating the hernia sac and abdominal cavity volume in complex large incisional hernia with loss of domain. *Hernia J Hernias Abdom Wall Surg* 14:63–69. <https://doi.org/10.1007/s10029-009-0560-8>
12. Baroudi R, Keppke EM, Netto FT (1974) Abdominoplasty. *Plast Reconstr Surg* 54:161–168
13. Muysoms F, Campanelli G, Champault GG, et al (2012) EuraHS: the development of an international online platform for registration and outcome measurement of ventral abdominal wall hernia repair. *Hernia J Hernias Abdom Wall Surg* 16:239–250. <https://doi.org/10.1007/s10029-012-0912-7>
14. Ventral Hernia Working Group, Breuing K, Butler CE, et al (2010) Incisional ventral hernias: review of the literature and recommendations regarding the grading and technique of repair. *Surgery* 148:544–558. <https://doi.org/10.1016/j.surg.2010.01.008>
15. Kanters AE, Krpata DM, Blatnik JA, et al (2012) Modified hernia grading scale to stratify surgical site occurrence after open ventral hernia repairs. *J Am Coll Surg* 215:787–793. <https://doi.org/10.1016/j.jamcollsurg.2012.08.012>



16. Berríos-Torres SI, Umscheid CA, Bratzler DW, et al (2017) Centers for Disease Control and Prevention Guideline for the Prevention of Surgical Site Infection, 2017. *JAMA Surg* 152:784–791. <https://doi.org/10.1001/jamasurg.2017.0904>
17. Clavien PA, Barkun J, de Oliveira ML, et al (2009) The Clavien-Dindo classification of surgical complications: five-year experience. *Ann Surg* 250:187–196. <https://doi.org/10.1097/SLA.0b013e3181b13ca2>
18. Kumar S, Edmunds RW, Dowdy C, et al (2018) Anterior versus Posterior Component Separation: Which Is Better? *Plast Reconstr Surg* 142:47S-53S. <https://doi.org/10.1097/PRS.0000000000004852>
19. de Vries Reilingh TS, van Goor H, Rosman C, et al (2003) “Components separation technique” for the repair of large abdominal wall hernias. *J Am Coll Surg* 196:32–37. [https://doi.org/10.1016/S1072-7515\(02\)01478-3](https://doi.org/10.1016/S1072-7515(02)01478-3)
20. Cornette B, De Bacquer D, Berrevoet F (2018) Component separation technique for giant incisional hernia: A systematic review. *Am J Surg* 215:719–726. <https://doi.org/10.1016/j.amjsurg.2017.07.032>
21. Saulis AS, Dumanian GA (2002) Periumbilical rectus abdominis perforator preservation significantly reduces superficial wound complications in “separation of parts” hernia repairs. *Plast Reconstr Surg* 109:2275–2280; discussion 2281–2282. <https://doi.org/10.1097/00006534-200206000-00016>
22. Alam NN, Narang SK, Pathak S, et al (2016) Methods of abdominal wall expansion for repair of incisional herniae: a systematic review. *Hernia* 20:191–199. <https://doi.org/10.1007/s10029-016-1463-0>
23. Motz BM, Schlosser KA, Heniford BT (2018) Chemical Components Separation: Concepts, Evidence, and Outcomes. *Plast Reconstr Surg* 142:58S-63S. <https://doi.org/10.1097/PRS.0000000000004856>
24. de Vries Reilingh TS, van Goor H, Charbon JA, et al (2007) Repair of giant midline abdominal wall hernias: “components separation technique” versus prosthetic repair : interim analysis of a randomized controlled trial. *World J Surg* 31:756–763. <https://doi.org/10.1007/s00268-006-0502-x>
25. Gonzalez R, Rehnke RD, Ramaswamy A, et al (2005) Components separation technique and laparoscopic approach: a review of two evolving strategies for ventral hernia repair. *Am Surg* 71:598–605
26. LeBlanc KA, Booth WV (1993) Laparoscopic repair of incisional abdominal hernias using expanded polytetrafluoroethylene: preliminary findings. *Surg Laparosc Endosc* 3:39–41
27. Lowe JB, Garza JR, Bowman JL, et al (2000) Endoscopically assisted “components separation” for closure of abdominal wall defects. *Plast Reconstr Surg* 105:720–729; quiz 730. <https://doi.org/10.1097/00006534-200002000-00039>
28. Maas SM, van Engeland M, Leeksa NG, Bleichrodt RP (1999) A modification of the “components separation” technique for closure of abdominal wall defects in the presence of an enterostomy. *J Am Coll Surg* 189:138–140. [https://doi.org/10.1016/s1072-7515\(99\)00067-8](https://doi.org/10.1016/s1072-7515(99)00067-8)
29. Rosen MJ, Williams C, Jin J, et al (2007) Laparoscopic versus open-component separation: a comparative analysis in a porcine model. *Am J Surg* 194:385–389. <https://doi.org/10.1016/j.amjsurg.2007.03.003>
30. Jensen KK, Henriksen NA, Jorgensen LN (2014) Endoscopic component separation for ventral hernia causes fewer wound complications compared to open components separation: a systematic review and meta-analysis. *Surg Endosc* 28:3046–3052. <https://doi.org/10.1007/s00464-014-3599-2>
31. Sauerland S, Walgenbach M, Habermalz B, et al (2011) Laparoscopic versus open surgical techniques for ventral or incisional hernia repair. *Cochrane Database Syst Rev* CD007781. <https://doi.org/10.1002/14651858.CD007781.pub2>
32. Forbes SS, Eskicioglu C, McLeod RS, Okrainec A (2009) Meta-analysis of randomized controlled trials comparing open and laparoscopic ventral and incisional hernia repair with mesh. *Br J Surg*

# APPENDIX

	Ramirez <i>et al</i> [6] (1990)	de Vries <i>et al</i> [19] (2003)	de Vries <i>et al</i> [24] (2007)	Carbonell <i>et al</i> [8] (2009)	Krpata <i>et al</i> [10] (2012)	Torregrosa <i>et al</i> [2] (2017)	Maloney <i>et al</i> [5] (2019)
Sample size ( <i>n</i> )	11	43	37	100	163	351	775
Mean age (years)	46,5 (?)	?	Ramirez: 53,9 (33 – 73) *PTFE: 58,7 (42 – 82)	58 (?)	ACS: 59,6 ±11,2 PCS: 54,7 ±11,7	51,6 ±23,2	58,8 ±11,5 ACS: 59,3 ±11,1 PCS: 58,5 ±11,7
BMI ( <i>kg/m</i> <sup>2</sup> )	?	27,3 ±4,5	Ramirez: 28,2 (23,9 – 38,7) PTFE: 28,7 (21,5 – 39,6)	?	ACS: 38,0 ±10,1 PCS: 32,5 ±7,0	32,3 ±1,3	33,6 ±7,1 ACS: 33,2 ±6,8 PCS: 33,8 ±7,2
Hernia defect size ( <i>cm</i> ) W: width L: length A: area	W: 4 – 18 L: 10 – 25	W: 13 ±7 L: 18 ±6	Ramirez: W: 15 (7 – 25) L: 25 (20 – 33) PTFE: W: 17 (9 – 30) L: 25 (20 – 30)	W: ? L: ? A: ?  82% (10 – 15 cm) 14% (>15 cm)	ACS: A: 531 ±324,3 PCS: A: 471,5 ±229,9	W: 13,3 ±3,9 L: 24,4 ±8,9	ACS: A: 379,5 ±265,2 PCS: A: 230,0 ±175,0
Surgical technique	Ramirez	Ramirez: 38 (88,4%) Maas: 5 (11,6%)	Ramirez: 19 (51,4%) PTFE: 18 (48,6%)	Ramirez modified by Carbonell-Bonafé	ACS: 56 (34,4%) PCS: 55 (33,7%) Laparoscopy: 52 (31,9%)	Ramirez modified by Torregrosa	ACS (259) PCS (516)
Mean surgical time ( <i>min</i> )	?	?	Ramirez: 113 (63 – 175) PTFE: 183 (135 – 254)	?	ACS: 285 (180 – 600) PCS: 228 (110 – 549)	197 ±7	ACS: 253,5 ±90,5 PCS: 201,9 ±59,8
Post-operative complications ( <i>n</i> )	None described	18 (41,9%) Respiratory: 2 Evisceration: 1	6 (16,2%) Ramirez Respiratory: 4 PTFE Respiratory: 2	?	?	20 (5,6%) Prolonged ileus: 9 (2,5%) Pneumonia: 5 (1,4%) Urinary infection: 3 (0,9%) Abdominal compartment syndrome: 2 (0,6%)	209 (27%) ARF**: 40 (6,8%) DVT***: 13 (1,7%) Pneumonia: 19 (2,5%) PE****: 21 (2,8%) Respiratory failure: 21 (2,8%)
Surgical site occurrence ( <i>n</i> )	None described	14 (32,6%) Hematoma: 5 Seroma: 2 Necrosis: 1 Infection: 6	23 (62,1%) Ramirez Hematoma: 1 Seroma: 4 Necrosis: 2 Infection: 3 PTFE Hematoma: 1 Seroma: 7 Necrosis: 3 Infection: 2	? Hematoma: ? Seroma: 12 Necrosis: 8 Infection: ?	ACS Major: 11 (19,6%) Minor: 16 (28,6%) PCS Major: 6 (10,9%) Minor: 8 (14,5%)	211 (60,1%) Hematoma: 32 (9,1%) Seroma: 123 (35,1%) Necrosis: 31 (8,8%) Infection: 25 (7,2%)	ACS Seroma: 34 (13,1%) Infection: 42 (16,2%) PSC Seroma: 69 (13,5%) Infection: 60 (11,6%)

Number of deaths ( <i>n</i> )	None described	1 (2,3%)	5 (13,5%) Ramirez: 4 PTFE: 1	1 (1%)	?	1 (0,3%)	7 (0,9%)
Mean follow-up period ( <i>months</i> )	? (4 – 42)	15,6 (12 – 30)	?	?	ACS: 9,1 (3 – 50,5) PSC: 6,8 (3 – 49,1)	32 (24 – 60)	23,3 ±25,1
Recurrence ( <i>n</i> )	None described	12 (32%)	21 (56,8%) Ramirez: 11 PTFE: 10	None	10 (6,1%) ACS: 8 (14,3%) PSC: 2 (3,6%)	29 (8,2%)	32 (4,1%) ACS: 18 (7%) PSC: 14 (2,7%)

\*PTFE: Intraoperative Polytetrafluoroethylene mesh.

\*\*ARF: Acute renal failure.

\*\*\* DVT: Deep vein thrombosis.

\*\*\*\*PE: Pulmonary embolism.

Table 5. Data extracted from main studies using the same surgical technique.