

## **COVID-19: AN EMERGING CAUSE OF ACUTE CEREBELITIS IN ADULTS?**

---

*Marcos Manoel Honorato*

Universidade do Estado do Pará (UEPA)  
Universidade Federal de São Paulo (UNIFESP)  
<http://orcid.org/0000-0002-9700-9938>

*Felipe Luan Lima da Silva*

Universidade do Estado do Pará (UEPA)  
<http://orcid.org/0000-0002-7942-9912>

*Adriane Cristina Vieira dos Santos*

Universidade do Estado do Pará (UEPA)  
<http://orcid.org/0000-0002-3452-7391>

*João Ferreira da Silva*

Universidade do Estado do Pará (UEPA)  
<http://orcid.org/0000-0003-3957-6907>

*Renata Maria de Carvalho Cremaschi*

Universidade Federal de São Paulo (UNIFESP)  
<http://orcid.org/0000-0002-8205-4816>

*Fernando Morgadinho Santos Coelho*

Universidade Federal de São Paulo (UNIFESP)  
<https://orcid.org/0000-0002-8482-3754>

All content in this magazine is licensed under a Creative Commons Attribution License. Attribution-Non-Commercial-Non-Derivatives 4.0 International (CC BY-NC-ND 4.0).



**Abstract:** The COVID-19 pandemic showed that SARS-CoV-2 is a neurotropic virus. Its biological cycle together with the host's immune response can cause numerous neurological manifestations. Headache and anosmia are common, but there have been reports of severe central and peripheral nervous system involvement, including acute cerebellitis. The authors describe the case of a young woman who presented a cerebellar syndrome in the recovery phase of the new coronavirus infection. The cerebrospinal fluid was altered, the neuroimaging was normal, as in most previously known post-infectious cerebellitis. She was treated with oral corticosteroids and the outcome was benign. The underlying mechanism is likely to be immune-mediated inflammation, possibly self-limited in most patients.

**Keywords:** COVID-19, Pandemics, Acute cerebellitis, Ataxia.

## INTRODUCTION

Acute cerebellitis is a syndrome characterized by onset cerebellar dysfunction over hours or days. It manifests itself through balance and gait disorder, appendicular coordination deficit, and there may be nystagmus and speech impairment. Nonspecific symptoms such as headache and vomiting are common. Although rare, it is a reason for hospitalization in children. (LANCELLA; ESPOSITO; GALLI; BOZZOLA et al., 2017).

The pathophysiological mechanism is uncertain and there are a variety of etiologies described in the literature, most of them viral or post-infectious. It is believed that the disease may result from direct aggression by the infectious agent or caused by the host's inflammatory response. Metabolic causes are less incident. (BOZZOLA; BOZZOLA; TOZZI; CALCATERRA et al., 2014).

The diagnosis is usually eminently clinical because only a minority of patients demonstrate an abnormality in neuroimaging exams. Cerebrospinal fluid analysis can also be of little value, and was normal in 67% of patients in a series of cases. (LANCELLA; ESPOSITO; GALLI; BOZZOLA et al., 2017).

Acute cerebellitis is a well-studied complication of chickenpox, when it can occur in up to 10.5% of patients who need to be hospitalized for this virus. Sixty percent of cases occurred in children under 5 years of age in a study in Italy. (BOZZOLA; BOZZOLA; TOZZI; CALCATERRA et al., 2014). Cases caused by coxsackie, Epstein Barr, human-herpes-virus 6, dengue, post-vaccinal etc. have already been reported (BOZZOLA; BOZZOLA; TOZZI; CALCATERRA et al., 2014; LANCELLA; ESPOSITO; GALLI; BOZZOLA et al., 2017).

Recently, with the advent of the new coronavirus pandemic, several neurological manifestations have been related to COVID19, mainly anosmia and headache. Some cases of patients with cerebellar symptoms have also been published. (CHAN; MURPHY; SARNA, 2021; DIEZMA-MARTÍN; MORALES-CASADO; ALVARADO; BERMEJO et al., 2020).

We describe a case of a young woman who presented with an acute cerebellar syndrome during recovery from COVID-19. Our study follows international bioethical standards for research on human beings and was authorized by the Research Ethics Committee of the State University of Pará, under opinion number 4.635.196.

## CASE

A 34-year-old woman, who was previously healthy, was evaluated with a history of fever, cough, myalgia, anosmia and ageusia of acute onset 3 weeks before, evolving in the last few days with severe, continuous non-pulsatile,

non-vomiting left hemicranial headache , associated with tremor, altered speech, gait and coordination. She got worse every day, and needed a wheelchair the day before. Husband reported irritability. She had had contact with people affected by COVID-19. She denied dyspnea. General clinical examination without abnormalities.

Neurological examination: awake, oriented, scanning dysarthria, unstable balance with eyes open or closed dysbasic unsupported gait, asymmetric dysmetria (worse on the left), dysdiachokinesia, kinetic tremor. Muscle strength was grade 5, deep reflexes were globally present, cutaneous-plantar reflex responded in bilateral flexion, and sensitivity was preserved. There were no nystagmus, fundus abnormalities, or signs of meningeal irritation.

Brain MR (Magnetic Resonance) did not show any abnormalities (Figure 1). dLCR (cerebrospinal fluid) analysis revealed a cloudy, xanthochromic aspect, with 06 cells (100% lymphocytes) and absence of red blood cells, protein dosage 125 mg/dℓ and glucose

76 mg/dℓ. The direct search for bacteria, fungi and resistant (BAAR - alcohol-acid bacilli) was negative and there was no bacterial growth in the culture medium. Reaction for syphilis and Pandy, as well as the search for oligoclonal bands were negative. Viral panel for herpes, CMV (Cytomegalovirus), dengue, HIV were also negative. Serological reaction by chemiluminescence technique detected a positive response for SARS-CoV2 virus in the IgM fraction (index 1.98) The IgG antibody fraction was negative (index 0.50). Computed tomography of the chest showed lesions peripheral lungs with ground-glass appearance, more peripheral location and affecting about 15% of the parenchyma, compatible with viral pneumonia.

There was complete and rapid regression of neurological signs and symptoms over two weeks, with the use of oral prednisolone 60mg/day for 10 days.

## DISCUSSION

COVID-19 is a new, extremely contagious disease caused by the virus called SARS-

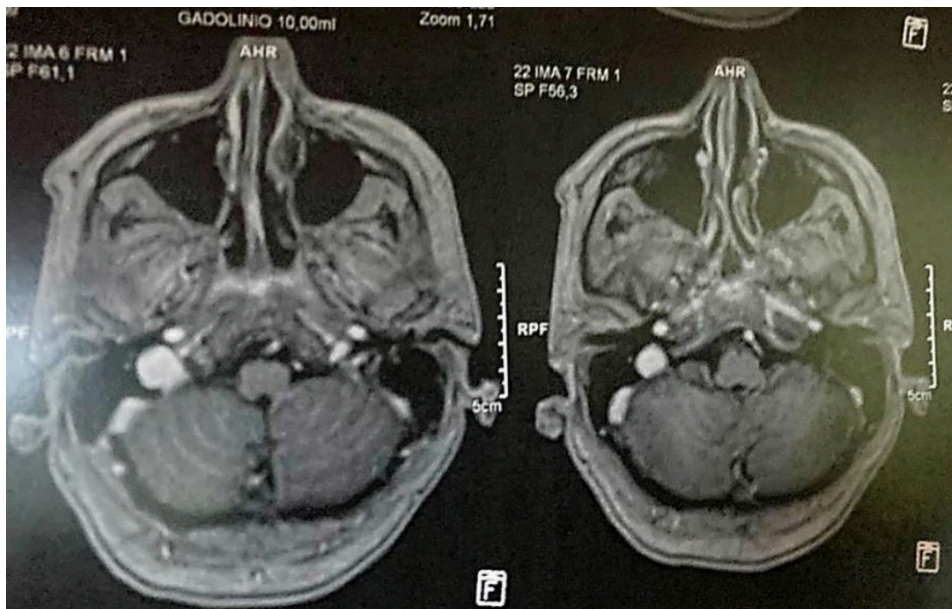


Figure 1. Magnetic resonance imaging of the brain in axial section, T1 sequence with contrast, no evidence of abnormalities in the cerebellum.

CoV-2. Although respiratory symptoms are often highlighted, COVID-19 is actually a multisystem disease, and can even affect the central nervous system. Several authors described frequent neurological symptoms among patients, especially the most severe, reaching 36% in a Chinese series. (ASADI-POOYA; SIMANI, 2020) Coronavirus neurotropism has been studied and the olfactory nerve has been shown to be a preferentially involved structure in the process (BAIG; KHALEEQ; ALI; SYEDA, 2020) There is still the possibility that the involvement of the central nervous system occurs through the receptors of the endothelial angiotensin-converting enzyme or by the breakdown of the blood-brain barrier mediated by cytokines. (DE BRITO; DA; DA SILVA, 2020).

Our patient had signs of an acute cerebellar syndrome, where tremor, axial and appendicular ataxia compromised coordination and gait. The diagnosis of an inflammatory process was supported by mild lymphocytic pleocytosis and increased CSF proteins, although the neuroimaging was normal.

Signs and symptoms compatible with cerebellitis occurred between the 3rd and 4th week of COVID-19, when there was no longer any viral activity in the body. Neurological symptoms developed acutely. She no longer had fever, but she had a severe headache. Clinical phenomena and late presentation of symptoms, as well as findings from complementary exams, suggested post-infectious inflammatory brain involvement, probably immune-mediated related to the new coronavirus. Cytokine storm and autoantibody production is supposed to be the underlying phenomenon. (FADAKAR; GHAEMMAGHAMI; MASOOMPOUR; YEGANEH *et al.*, 2020).

Similar cases have been reported, also in the recovery phase of COVID-19. In

most of them, neuroimaging and CSF were normal, different from our patient. (DAR; WANI; YAQOOB; ASIMI *et al.*, 2021; DIEZMA-MARTÍN; MORALES-CASADO; ALVARADO; BERMEJO *et al.*, 2020; FADAKAR; GHAEMMAGHAMI; MASOOMPOUR; YEGANEH *et al.*, 2020; POVLOW; AUERBACH, 2021). This phenomenon was already described as being common in patients with other acute post-viral cerebellitis. (LANCELLA; ESPOSITO; GALLI; BOZZOLA *et al.*, 2017).

The patient under study showed progressive improvement in a few days, restoring balance and independent gait, using oral corticosteroid therapy.

Central and peripheral nervous system autoimmune complications are often treated with pulse therapy (intravenous methylprednisolone), hyperimmune immunoglobulin, or plasmapheresis. But there is no consensus on this, because most of the acute cerebellitis described before the pandemic had a benign evolution, as in the case of our patient, although some cases evolved with edema and tonsillar herniation. Altered neuroimaging seems to be the statistically significant risk factor for an unsatisfactory outcome. (LANCELLA; ESPOSITO; GALLI; BOZZOLA *et al.*, 2017).

The data suggest that post-covid immune-mediated cerebellitis is a clinical entity that affects adults and has a benign course and self-limited course.

More studies are needed regarding the pathophysiology, observation and description of other cases of this emerging disease so that we can better define the essential points for diagnosis and more assertive conduct, ensuring a better outcome for patients.

Cerebellitis is one of the numerous manifestations related to the nervous system that have become a real challenge to the practice of neurologists during the pandemic.

Its diagnosis and management needs to be better studied so that the most assertive conduct can be taken.

Marcos Manoel Honorato was responsible for patient care, project design, data collection from the medical record and writing of the article. Adriane Cristina Vieira dos Santos, Felipe Luan Lima da Silva and João Ferreira da Silva did bibliographical research. Renata Maria de Carvalho Cremaschi and Fernando Morgadinho Santos Coelho adjusted, corrected and concluded the discussion.

## INTEREST CONFLICTS

There is not any.

## REFERENCES

- ASADI-POOYA, A. A.; SIMANI, L. Central nervous system manifestations of COVID-19: a systematic review. **Journal of the neurological sciences**, 413, p. 116832, 2020.
- BAIG, A. M.; KHALEEQ, A.; ALI, U.; SYEDA, H. Evidence of the COVID-19 virus targeting the CNS: tissue distribution, host-virus interaction, and proposed neurotropic mechanisms. **ACS chemical neuroscience**, 11, n. 7, p. 995-998, 2020.
- BOZZOLA, E.; BOZZOLA, M.; TOZZI, A. E.; CALCATERRA, V. *et al.* Acute cerebellitis in varicella: a ten year case series and systematic review of the literature. **Italian journal of pediatrics**, 40, n. 1, p. 1-5, 2014.
- CHAN, J. L.; MURPHY, K. A.; SARNA, J. R. Myoclonus and cerebellar ataxia associated with COVID-19: a case report and systematic review. **Journal of Neurology**, p. 1-32, 2021.
- DAR, W.; WANI, M.; YAQOOB, A.; ASIMI, R. *et al.* Para-infectious cerebellar ataxia post Covid 19 infection. **Neurology Asia**, 26, n. 1, p. 197-198, 2021.
- DE BRITO, W. G. F.; DA SILVA, J. P. D. O. Impactos neuropatológicos do COVID-19. **Brazilian Journal of Health Review**, 3, n. 3, p. 4227-4235, 2020.
- DIEZMA-MARTÍN, A.; MORALES-CASADO, M.; ALVARADO, N. G.; BERMEJO, A. V. *et al.* Tremor and ataxia in COVID-19. **Neurología (English Edition)**, 35, n. 6, p. 409, 2020.
- FADAKAR, N.; GHAEMMAGHAMI, S.; MASOOMPOUR, S. M.; YEGANEH, B. S. *et al.* A first case of acute cerebellitis associated with coronavirus disease (COVID-19): a case report and literature review. **The Cerebellum**, 19, n. 6, p. 911-914, 2020.
- LANCELLA, L.; ESPOSITO, S.; GALLI, M. L.; BOZZOLA, E. *et al.* Acute cerebellitis in children: an eleven year retrospective multicentric study in Italy. **Italian journal of pediatrics**, 43, n. 1, p. 1-10, 2017.
- POVLOW, A.; AUERBACH, A. J. Acute cerebellar ataxia in COVID-19 infection: a case report. **The Journal of Emergency Medicine**, 60, n. 1, p. 73-76, 2021.